

# Examination of the degenerative hand

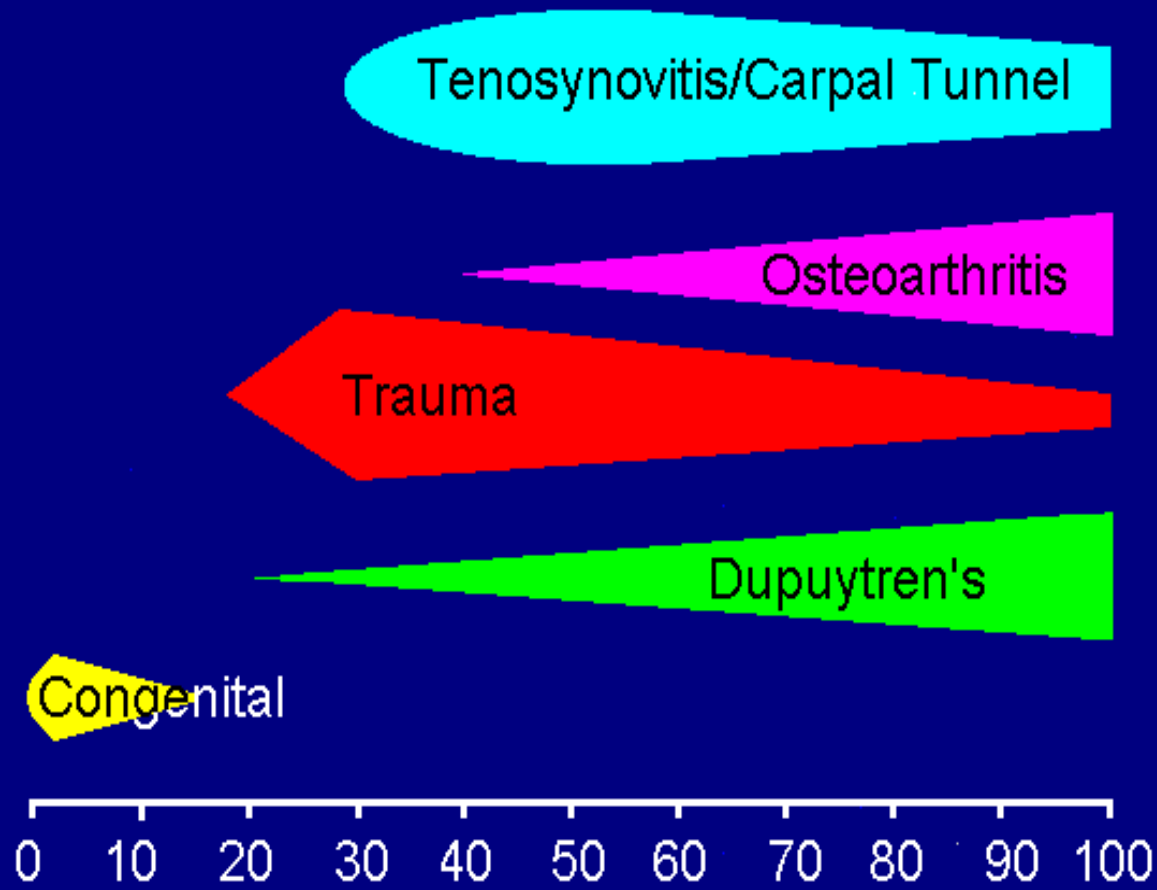
H.J.C.R. Belcher

Queen Victoria Hospital,

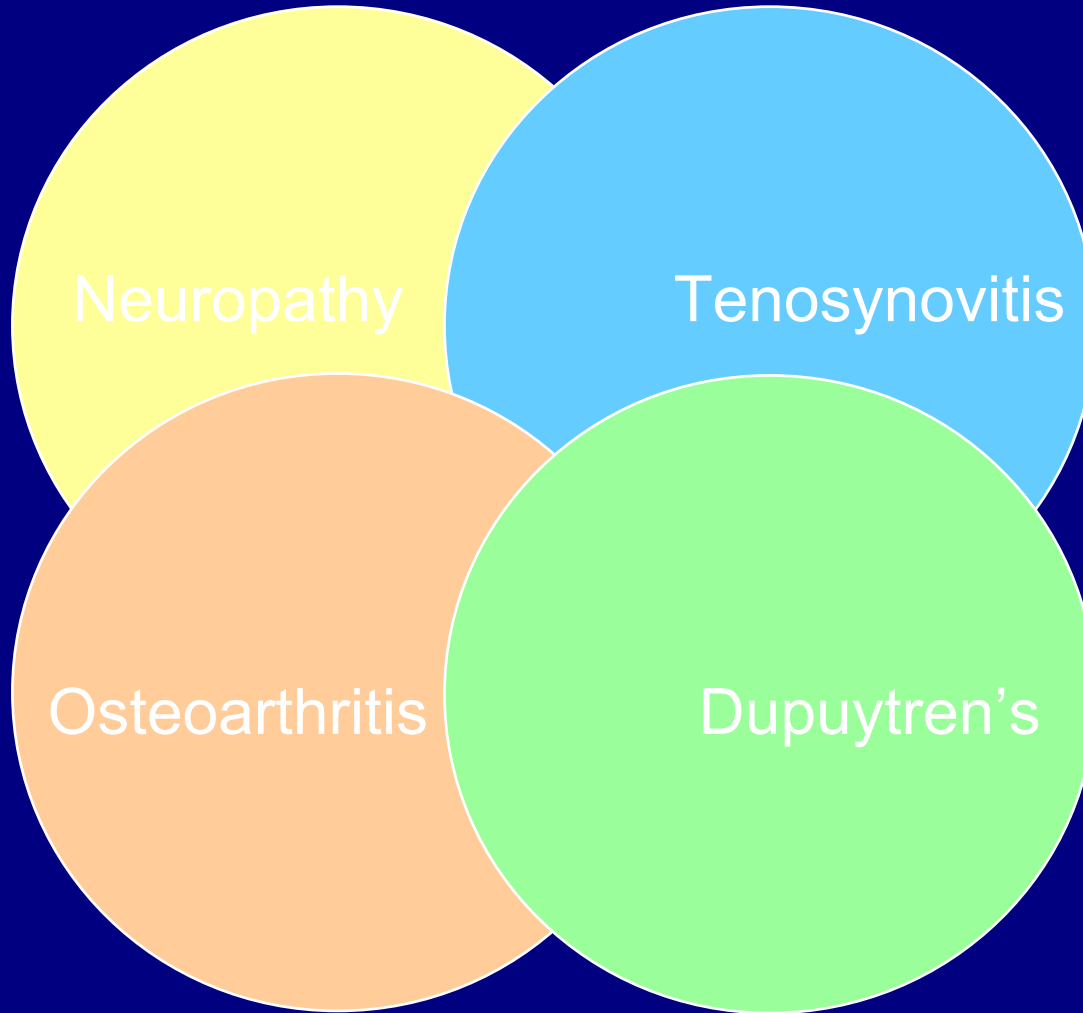
East Grinstead



# Ages of Man



# Degeneration



# Conditions

Carpal tunnel syndrome

Cubital tunnel syndrome

Flexor tenosynovitis

De Quervain's tenovaginitis

Sagittal band rupture

Dupuytren's contracture

TMCJ osteoarthritis

STT osteoarthritis

PTq osteoarthritis

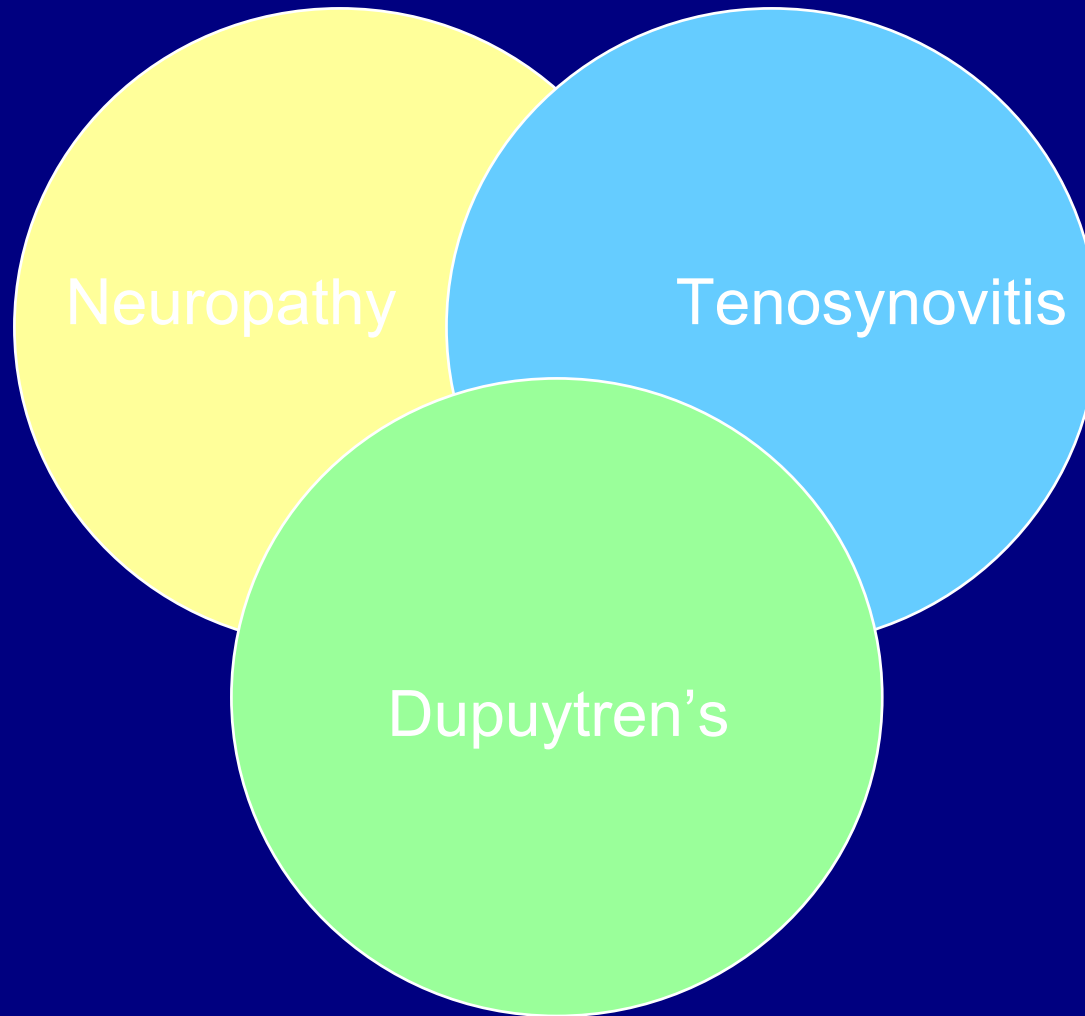
DRUJ osteoarthritis

TFCC degeneration

Digital osteoarthritis

Other

# Diabetic stiff hand



# Sequence

Look

Feel

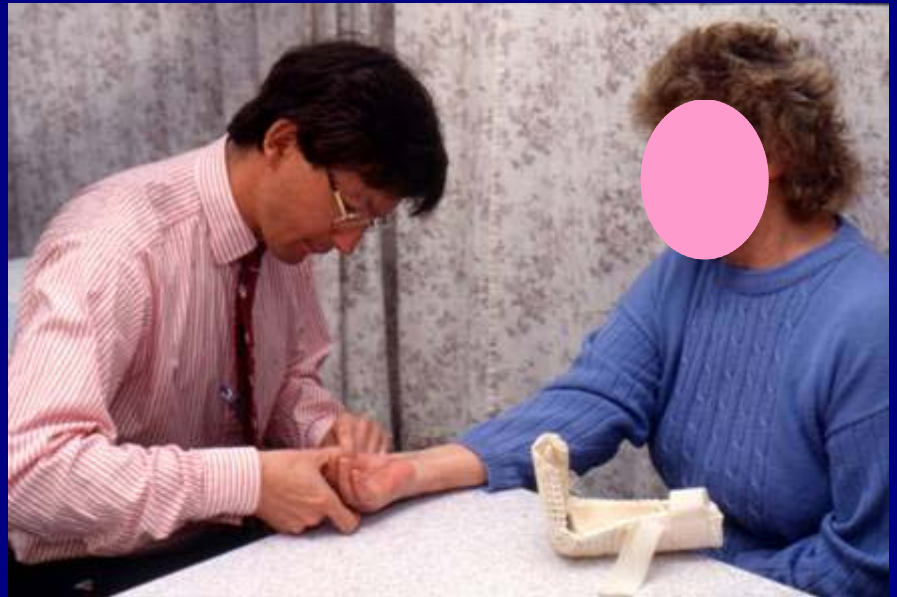Move

Provoke

Quantify

# Examination technique

Ask relevant questions  
Purposeful examination  
Focused examination  
Clear end points



# End points

Diagnosis

Quantification

Investigations

Treatment

# Look

Carpal tunnel syndrome

Cubital tunnel syndrome

Flexor tenosynovitis

De Quervain's tenovaginitis

Sagittal band rupture

Dupuytren's contracture

TMCJ osteoarthritis

STT osteoarthritis

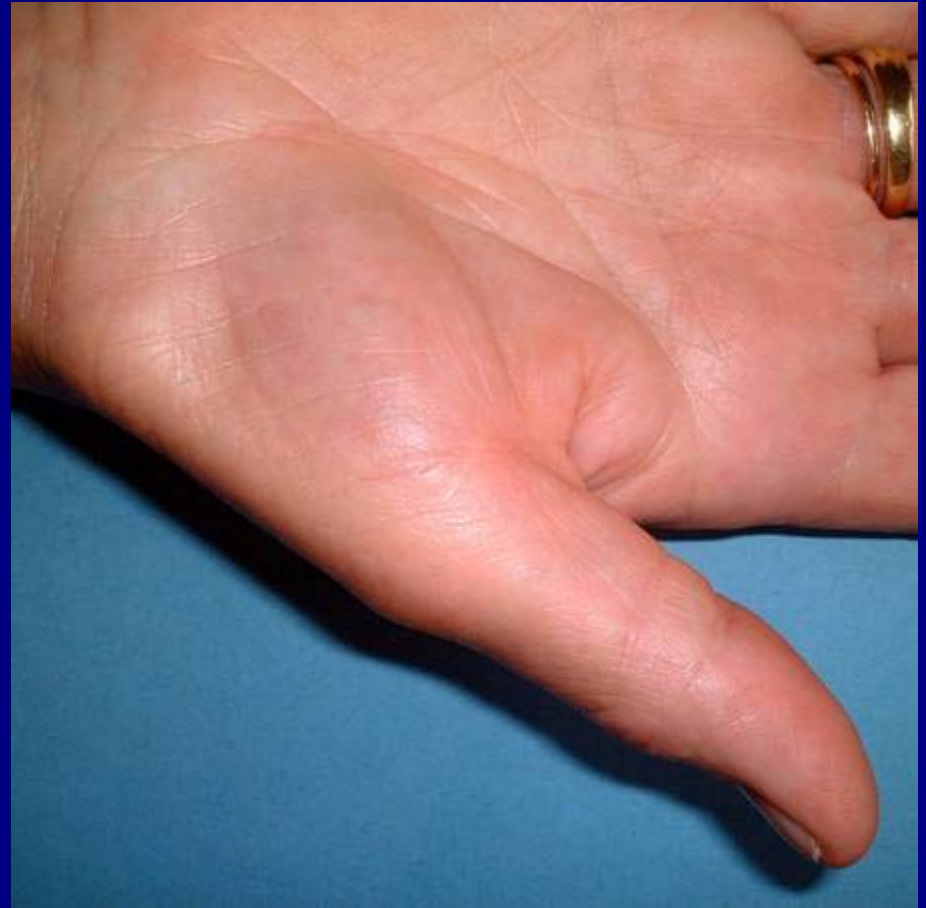PTq osteoarthritis

DRUJ osteoarthritis

TFCC degeneration

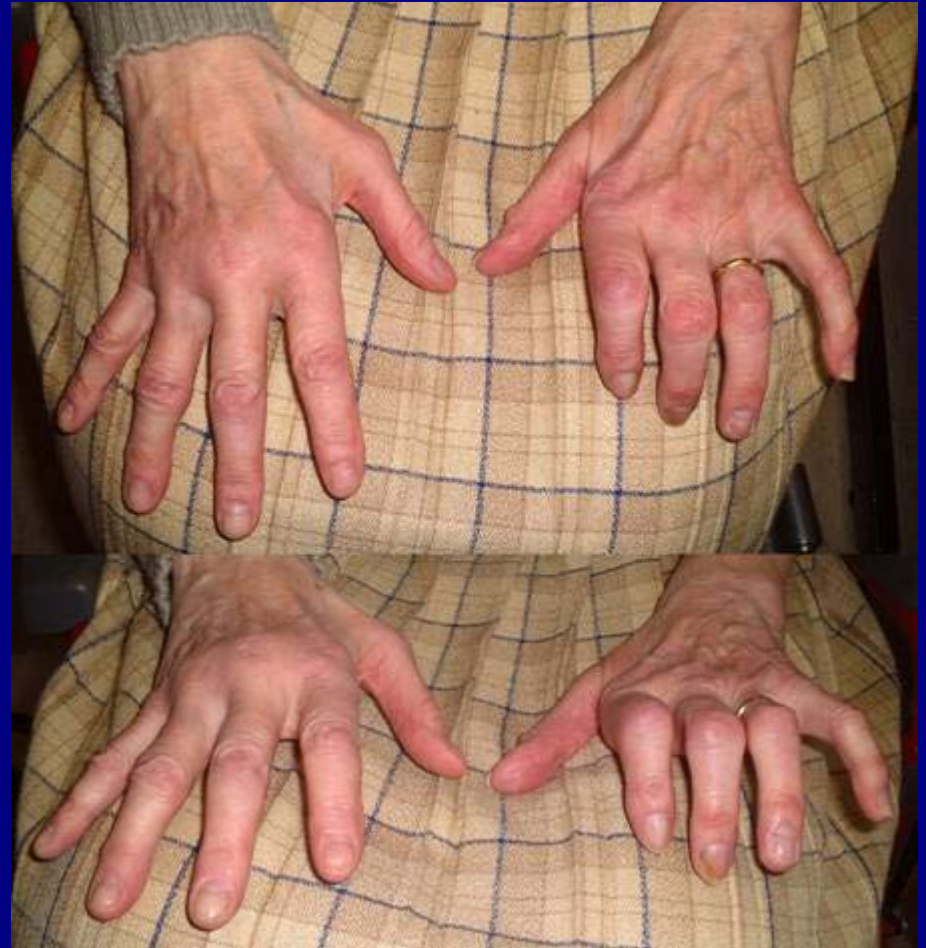Digital osteoarthritis

Other



# Look

- Carpal tunnel syndrome
- Cubital tunnel syndrome
- Flexor tenosynovitis
- De Quervain's tenovaginitis
- Sagittal band rupture
- Dupuytren's contracture
- TMCJ osteoarthritis
- STT osteoarthritis
- PTq osteoarthritis
- DRUJ osteoarthritis
- TFCC degeneration
- Digital osteoarthritis
- Other



# Look

Carpal tunnel syndrome

Cubital tunnel syndrome

**Flexor tenosynovitis**

De Quervain's tenovaginitis

Sagittal band rupture

Dupuytren's contracture

TMCJ osteoarthritis

STT osteoarthritis

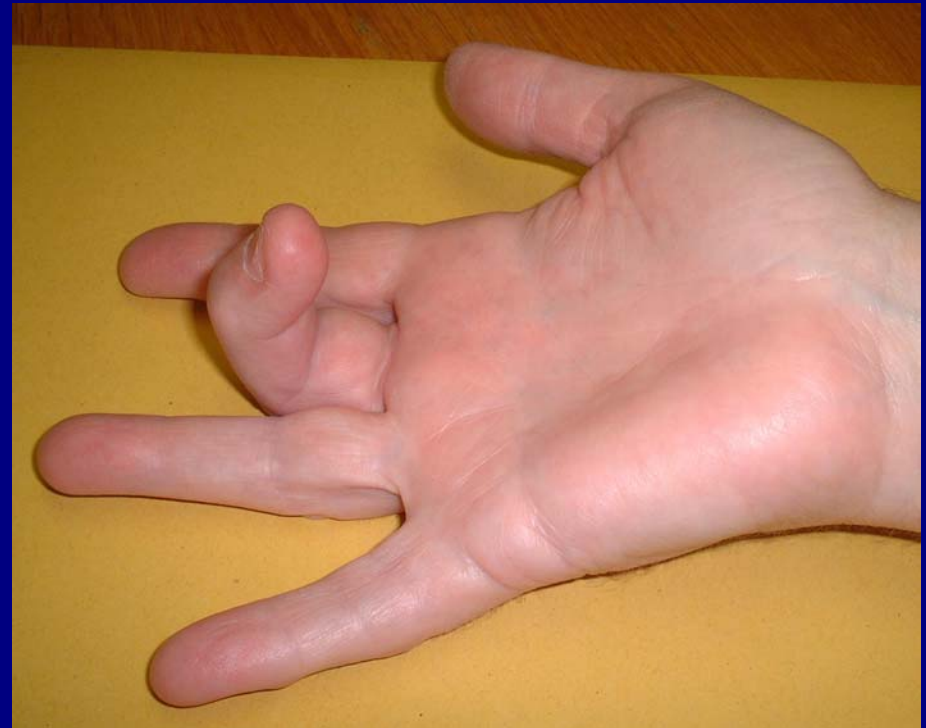PTq osteoarthritis

DRUJ osteoarthritis

TFCC degeneration

Digital osteoarthritis

Other



# Look

Carpal tunnel syndrome

Cubital tunnel syndrome

Flexor tenosynovitis

**De Quervain's tenovaginitis**

Sagittal band rupture

Dupuytren's contracture

TMCJ osteoarthritis

STT osteoarthritis

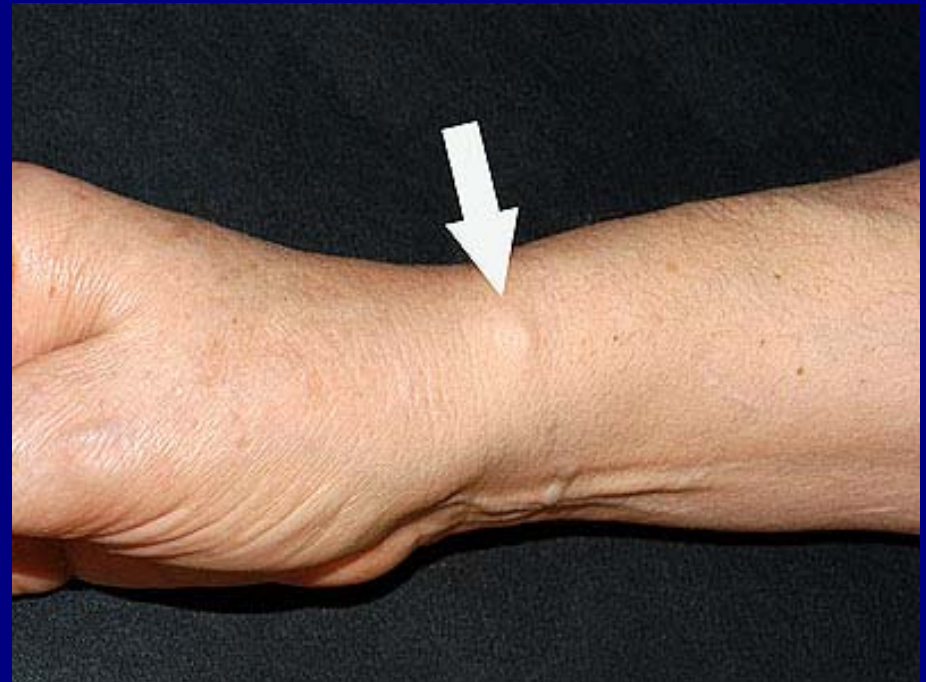
PTq osteoarthritis

DRUJ osteoarthritis

TFCC degeneration

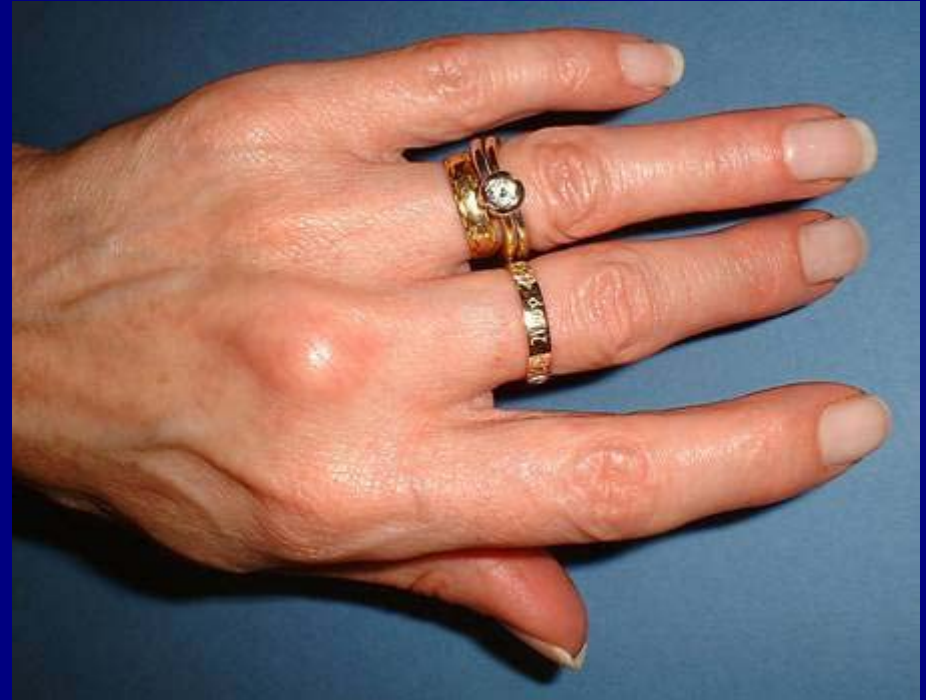Digital osteoarthritis

Other



# Look

- Carpal tunnel syndrome
- Cubital tunnel syndrome
- Flexor tenosynovitis
- De Quervain's tenovaginitis
- Sagittal band rupture**
- Dupuytren's contracture
- TMCJ osteoarthritis
- STT osteoarthritis
- PTq osteoarthritis
- DRUJ osteoarthritis
- TFCC degeneration
- Digital osteoarthritis
- Other



# Look

Carpal tunnel syndrome

Cubital tunnel syndrome

Flexor tenosynovitis

De Quervain's tenovaginitis

Sagittal band rupture

Dupuytren's contracture

TMCJ osteoarthritis

STT osteoarthritis

PTq osteoarthritis

DRUJ osteoarthritis

TFCC degeneration

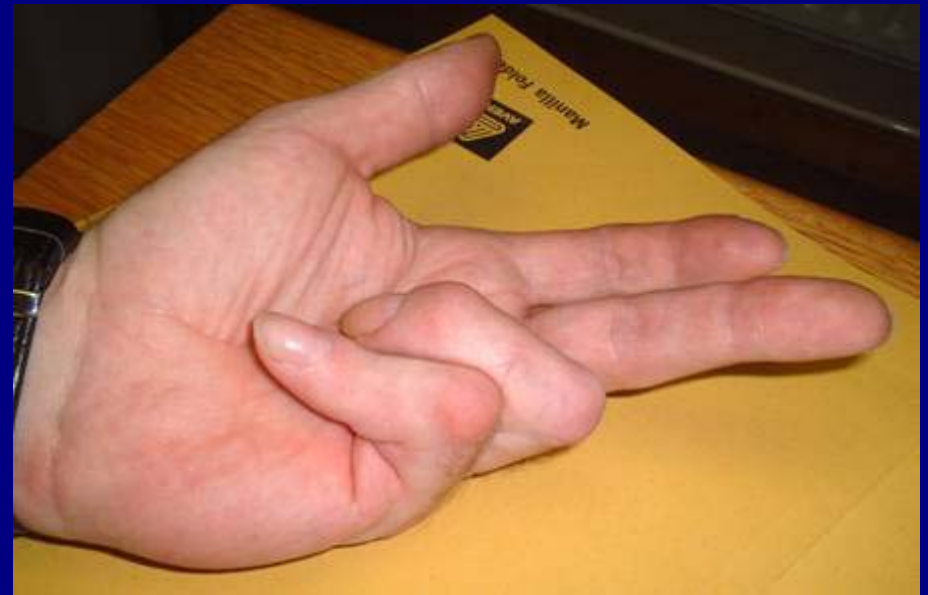Digital osteoarthritis

Other

Severity

Diathesis

Skin



# Look

Carpal tunnel syndrome

Cubital tunnel syndrome

Flexor tenosynovitis

De Quervain's tenovaginitis

Sagittal band rupture

Dupuytren's contracture

TMCJ osteoarthritis

STT osteoarthritis

PTq osteoarthritis

DRUJ osteoarthritis

TFCC degeneration

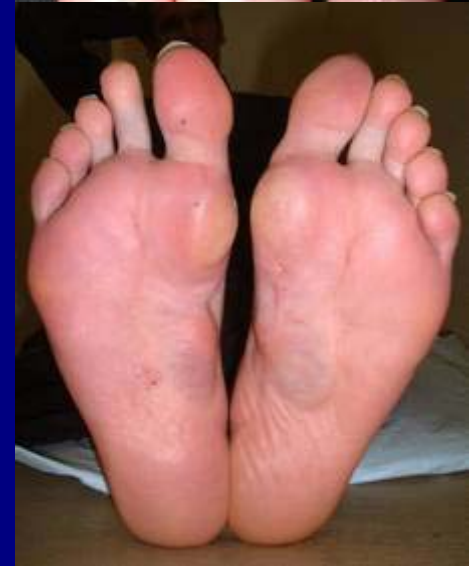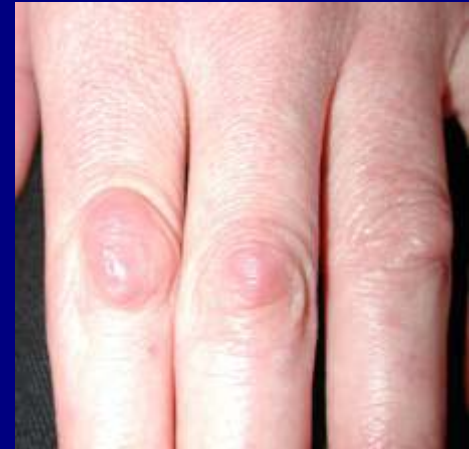Digital osteoarthritis

Other

Severity

Diathesis

Skin



# Look

Carpal tunnel syndrome

Cubital tunnel syndrome

Flexor tenosynovitis

De Quervain's tenovaginitis

Sagittal band rupture

Dupuytren's contracture

TMCJ osteoarthritis

STT osteoarthritis

PTq osteoarthritis

DRUJ osteoarthritis

TFCC degeneration

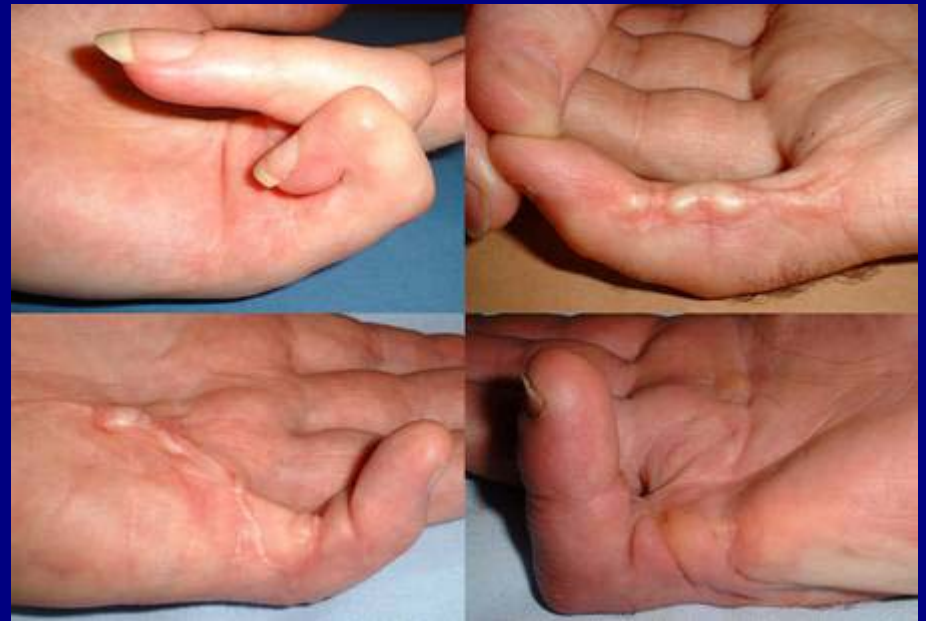Digital osteoarthritis

Other

Severity

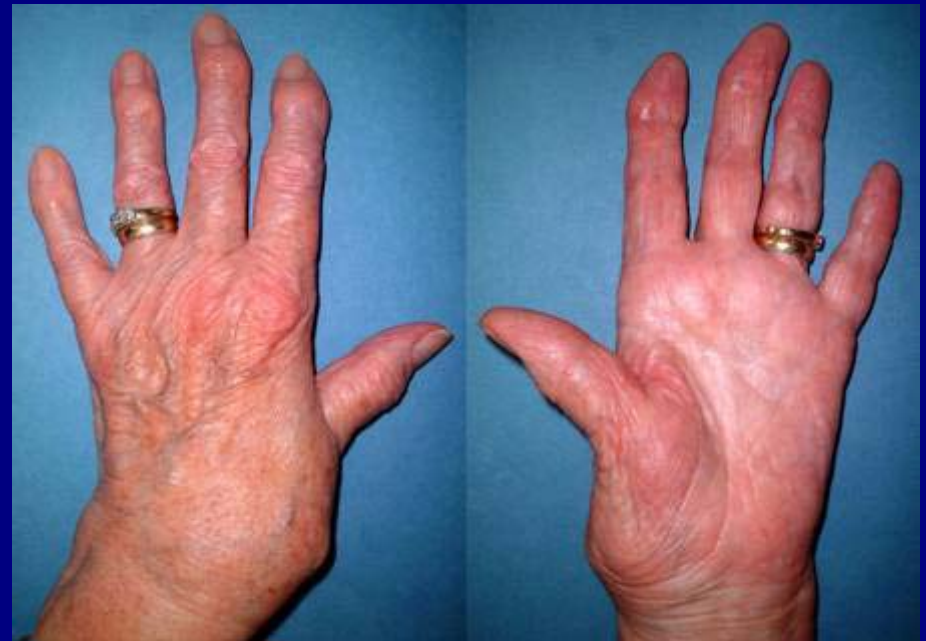Diathesis

Skin



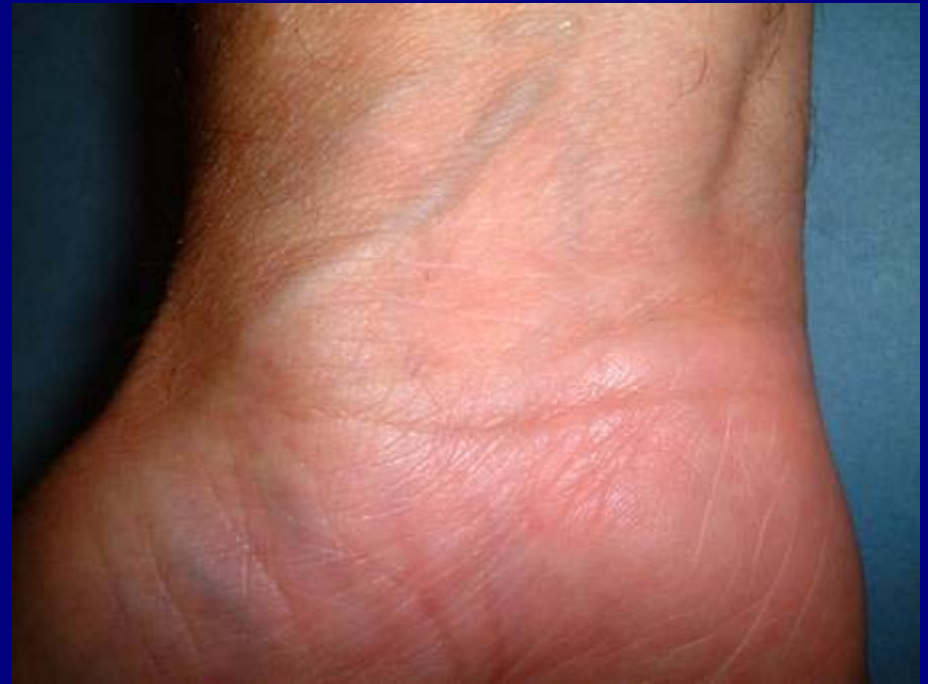# Look

- Carpal tunnel syndrome
- Cubital tunnel syndrome
- Flexor tenosynovitis
- De Quervain's tenovaginitis
- Sagittal band rupture
- Dupuytren's contracture
- TMCJ osteoarthritis**
- STT osteoarthritis
- PTq osteoarthritis
- DRUJ osteoarthritis
- TFCC degeneration
- Digital osteoarthritis
- Other



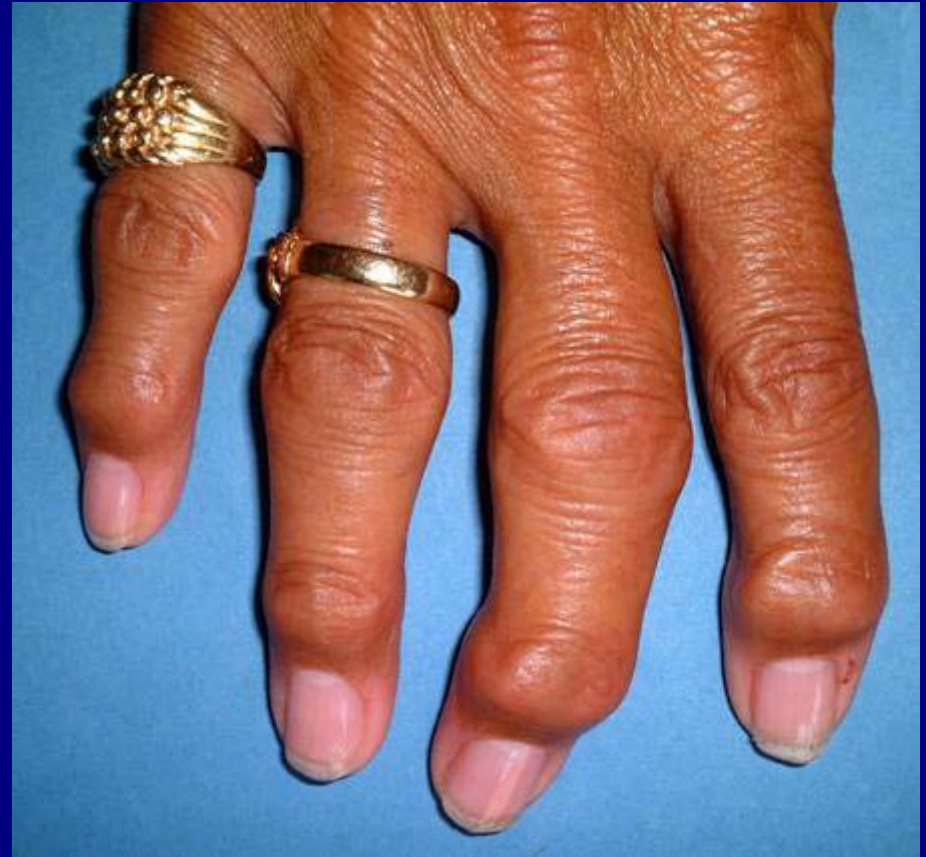# Look

- Carpal tunnel syndrome
- Cubital tunnel syndrome
- Flexor tenosynovitis
- De Quervain's tenovaginitis
- Sagittal band rupture
- Dupuytren's contracture
- TMCJ osteoarthritis
- STT osteoarthritis**
- PTq osteoarthritis**
- DRUJ osteoarthritis**
- TFCC degeneration**
- Digital osteoarthritis
- Other



# Look

- Carpal tunnel syndrome
- Cubital tunnel syndrome
- Flexor tenosynovitis
- De Quervain's tenovaginitis
- Sagittal band rupture
- Dupuytren's contracture
- TMCJ osteoarthritis
- STT osteoarthritis
- PTq osteoarthritis
- DRUJ osteoarthritis
- TFCC degeneration
- Digital osteoarthritis**
- Other

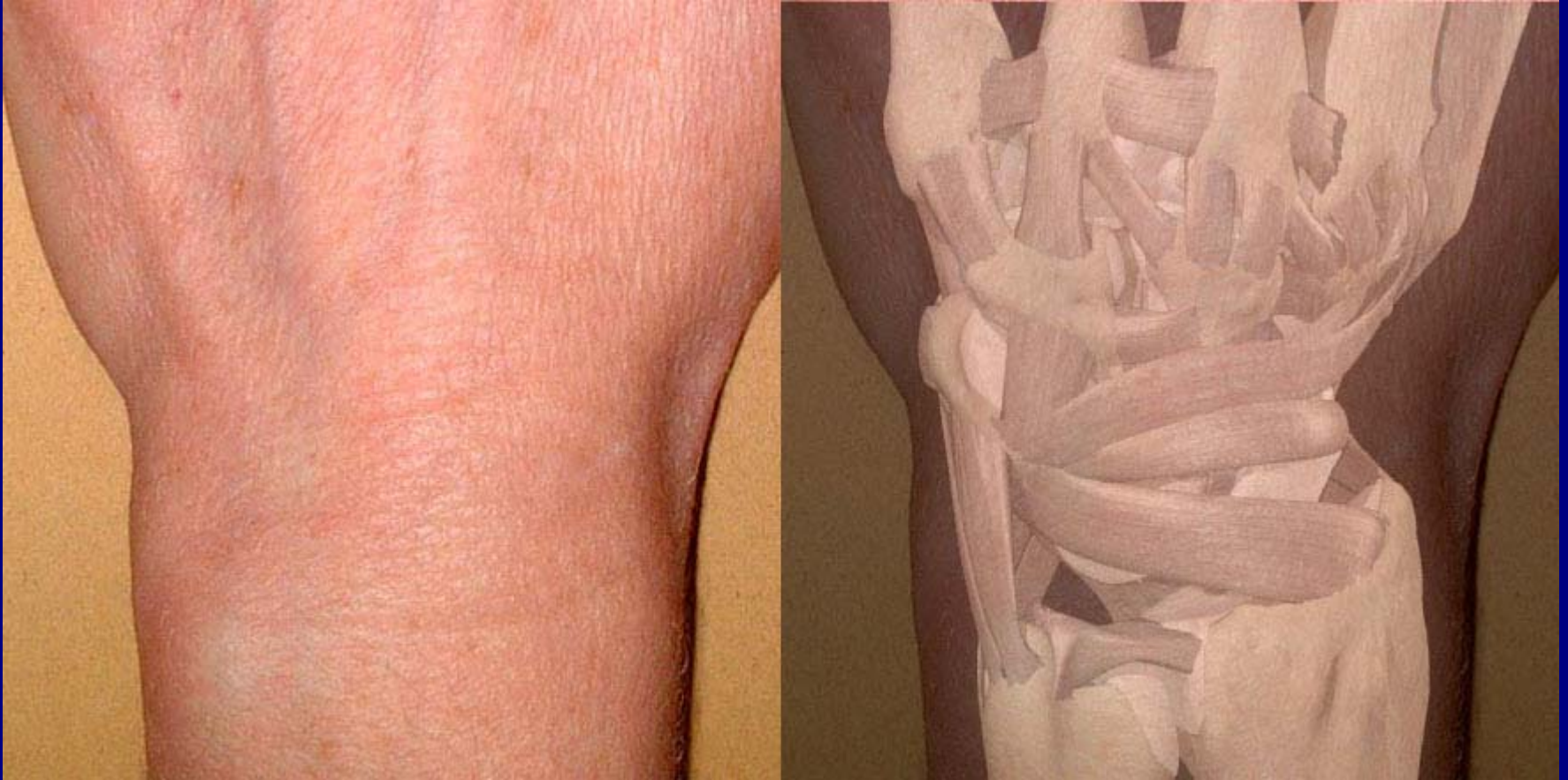

# Look

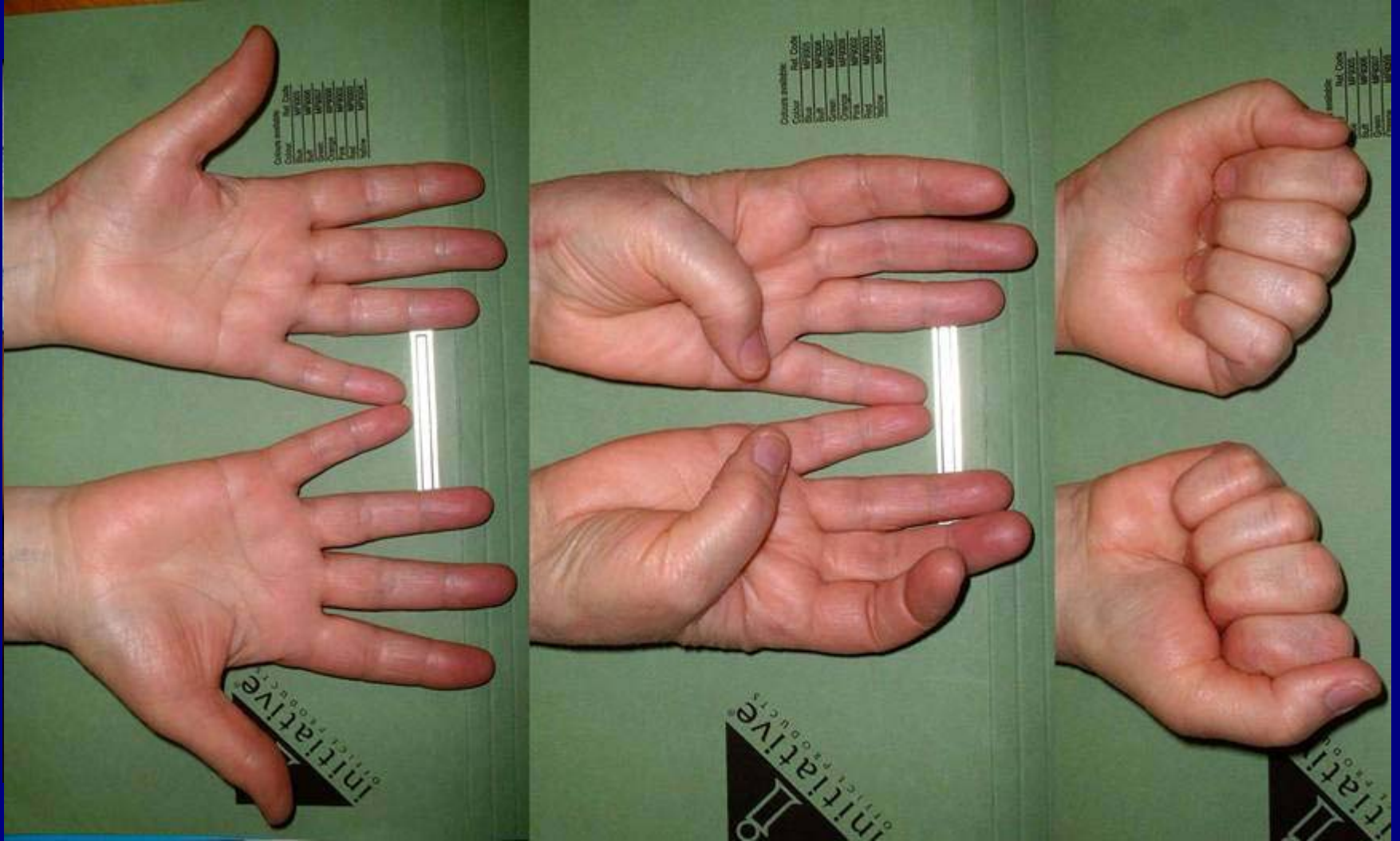Carpal tunnel syndrome  
Cubital tunnel syndrome  
Flexor tenosynovitis  
De Quervain's tenovaginitis  
Sagittal band rupture  
Dupuytren's contracture  
TMCJ osteoarthritis  
STT osteoarthritis  
PTq osteoarthritis  
DRUJ osteoarthritis  
TFCC degeneration  
Digital osteoarthritis  
**Diabetic stiff hand**



# Feel



# Move



# Move

Carpal tunnel syndrome

Cubital tunnel syndrome

**Flexor tenosynovitis**

De Quervain's tenovaginitis

Sagittal band rupture

Dupuytren's contracture

TMCJ osteoarthritis

STT osteoarthritis

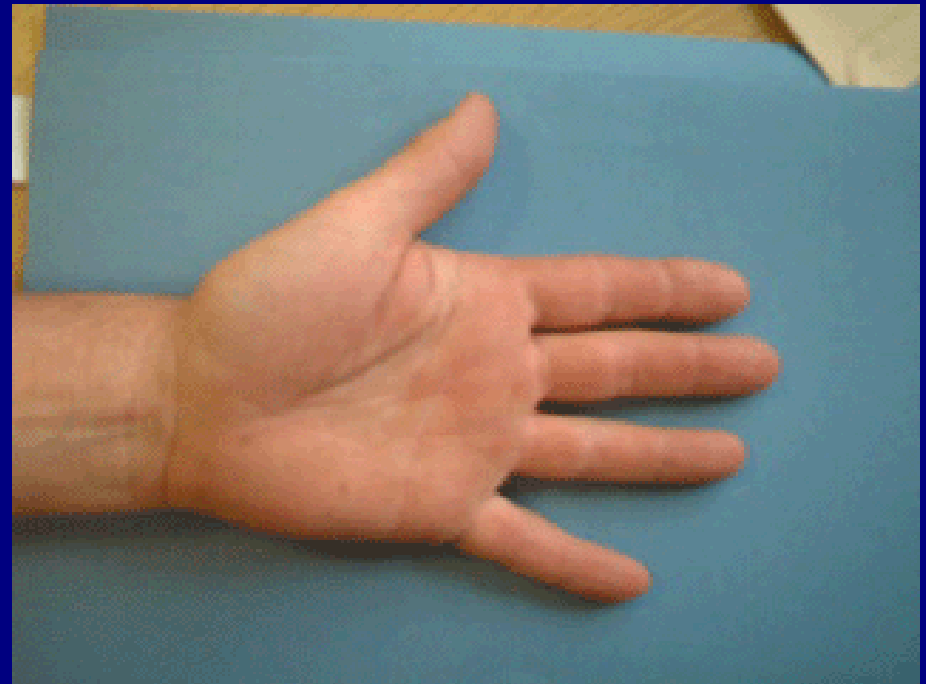
PTq osteoarthritis

DRUJ osteoarthritis

TFCC degeneration

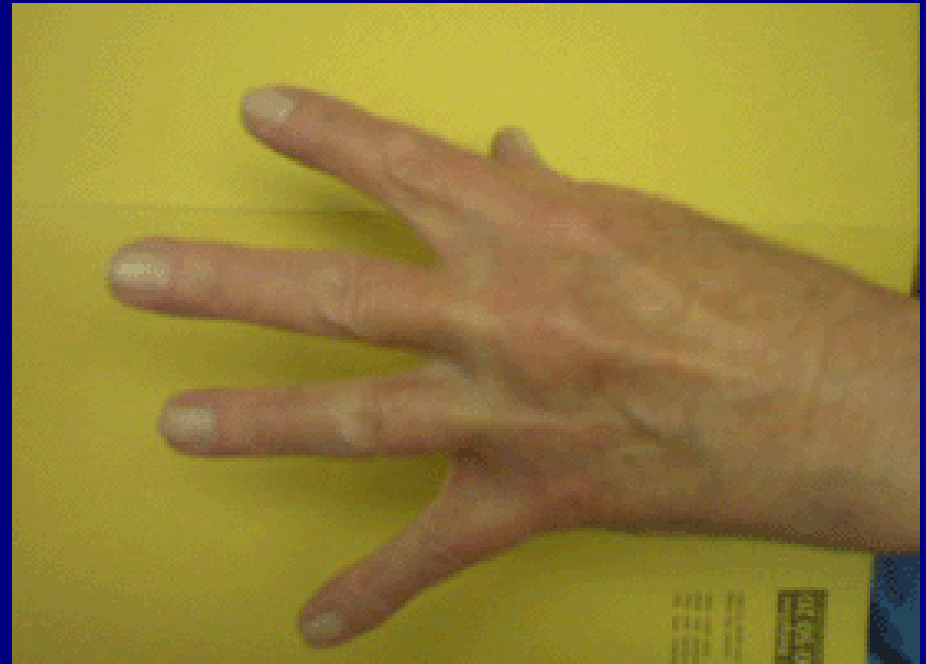Digital osteoarthritis

Other



# Move

- Carpal tunnel syndrome
- Cubital tunnel syndrome
- Flexor tenosynovitis
- De Quervain's tenovaginitis
- Sagittal band rupture**
- Dupuytren's contracture
- TMCJ osteoarthritis
- STT osteoarthritis
- PTq osteoarthritis
- DRUJ osteoarthritis
- TFCC degeneration
- Digital osteoarthritis
- Other



# Move

Carpal tunnel syndrome

Cubital tunnel syndrome

Flexor tenosynovitis

De Quervain's tenovaginitis

**Sagittal band rupture**

Dupuytren's contracture

TMCJ osteoarthritis

STT osteoarthritis

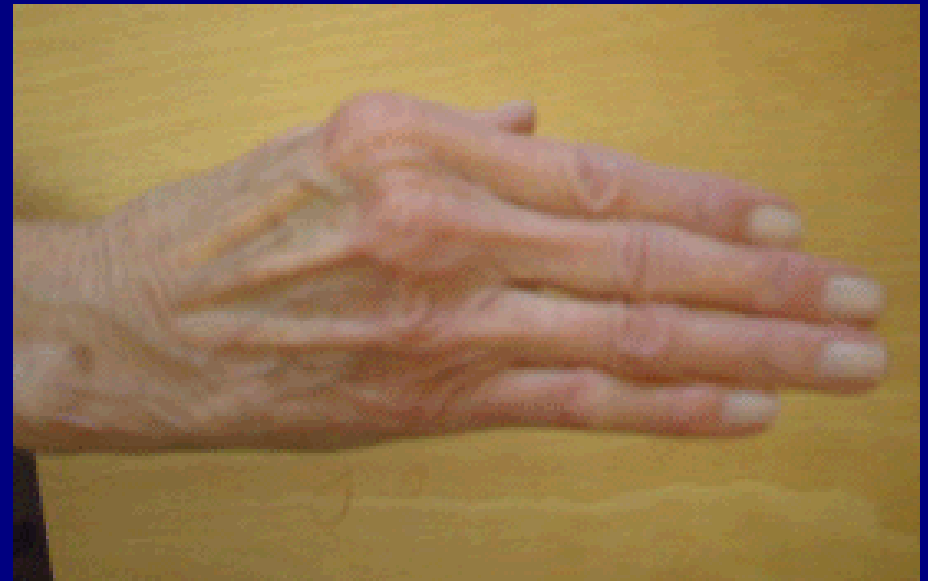PTq osteoarthritis

DRUJ osteoarthritis

TFCC degeneration

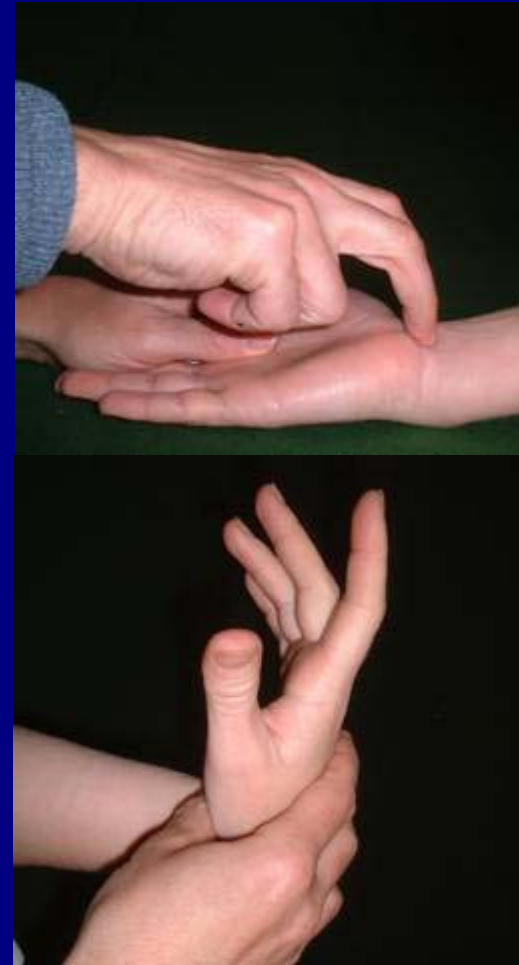Digital osteoarthritis

Other



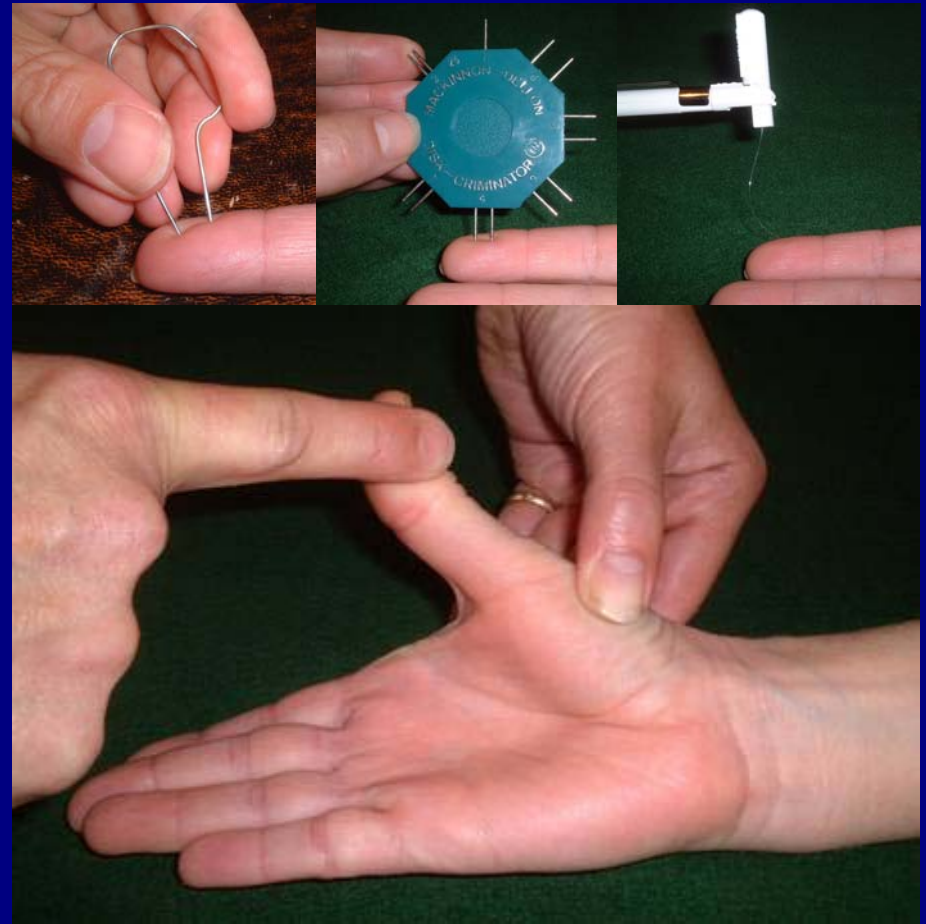
# Provoke

Carpal tunnel syndrome  
Cubital tunnel syndrome  
Flexor tenosynovitis  
De Quervain's tenovaginitis  
Sagittal band rupture  
Dupuytren's contracture  
TMCJ osteoarthritis  
STT osteoarthritis  
PTq osteoarthritis  
DRUJ osteoarthritis  
TFCC degeneration  
Digital osteoarthritis  
Other



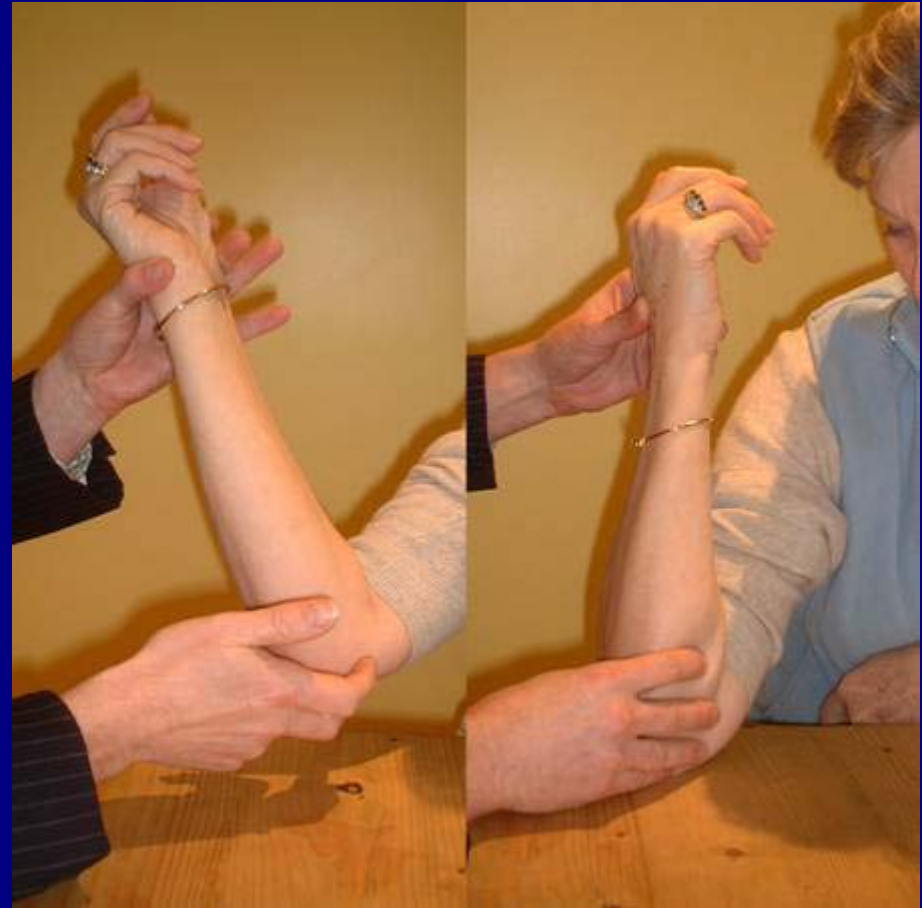# Quantify

- Carpal tunnel syndrome
- Cubital tunnel syndrome
- Flexor tenosynovitis
- De Quervain's tenovaginitis
- Sagittal band rupture
- Dupuytren's contracture
- TMCJ osteoarthritis
- STT osteoarthritis
- PTq osteoarthritis
- DRUJ osteoarthritis
- TFCC degeneration
- Digital osteoarthritis
- Other



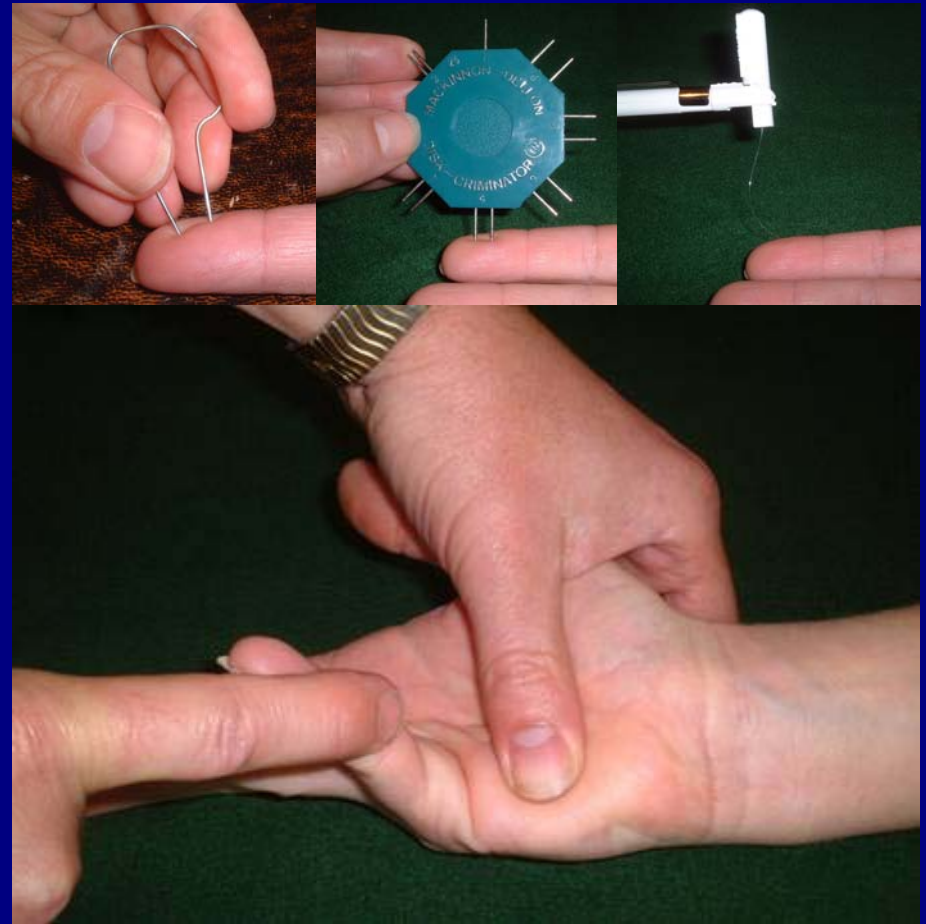
# Provoke

- Carpal tunnel syndrome
- Cubital tunnel syndrome
- Flexor tenosynovitis
- De Quervain's tenovaginitis
- Sagittal band rupture
- Dupuytren's contracture
- TMCJ osteoarthritis
- STT osteoarthritis
- PTq osteoarthritis
- DRUJ osteoarthritis
- TFCC degeneration
- Digital osteoarthritis
- Other



# Quantify

Carpal tunnel syndrome  
Cubital tunnel syndrome  
Flexor tenosynovitis  
De Quervain's tenovaginitis  
Sagittal band rupture  
Dupuytren's contracture  
TMCJ osteoarthritis  
STT osteoarthritis  
PTq osteoarthritis  
DRUJ osteoarthritis  
TFCC degeneration  
Digital osteoarthritis  
Other



# Quantify

Carpal tunnel syndrome

Cubital tunnel syndrome

**Flexor tenosynovitis**

De Quervain's tenovaginitis

Sagittal band rupture

Dupuytren's contracture

TMCJ osteoarthritis

STT osteoarthritis

PTq osteoarthritis

DRUJ osteoarthritis

TFCC degeneration

Digital osteoarthritis

Other



# Provoke

Carpal tunnel syndrome

Cubital tunnel syndrome

Flexor tenosynovitis

**De Quervain's tenovaginitis**

Sagittal band rupture

Dupuytren's contracture

TMCJ osteoarthritis

STT osteoarthritis

PTq osteoarthritis

DRUJ osteoarthritis

TFCC degeneration

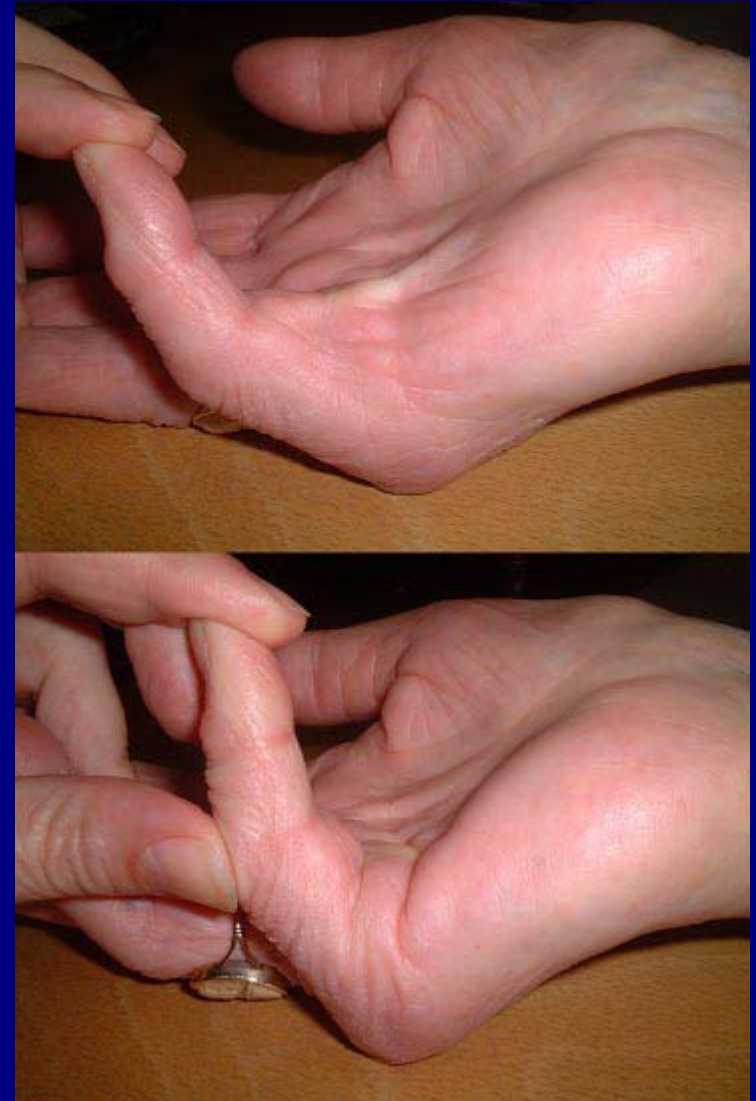
Digital osteoarthritis

Other



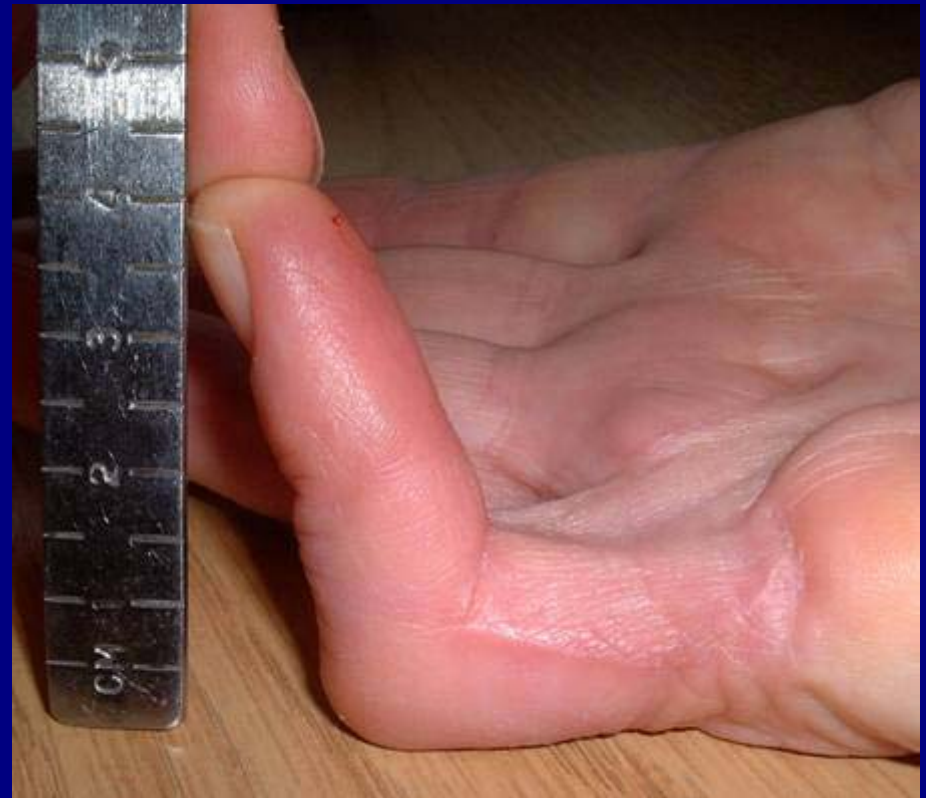# Move

- Carpal tunnel syndrome
- Cubital tunnel syndrome
- Flexor tenosynovitis
- De Quervain's tenovaginitis
- Sagittal band rupture
- Dupuytren's contracture**
- TMCJ osteoarthritis
- STT osteoarthritis
- PTq osteoarthritis
- DRUJ osteoarthritis
- TFCC degeneration
- Digital osteoarthritis
- Other



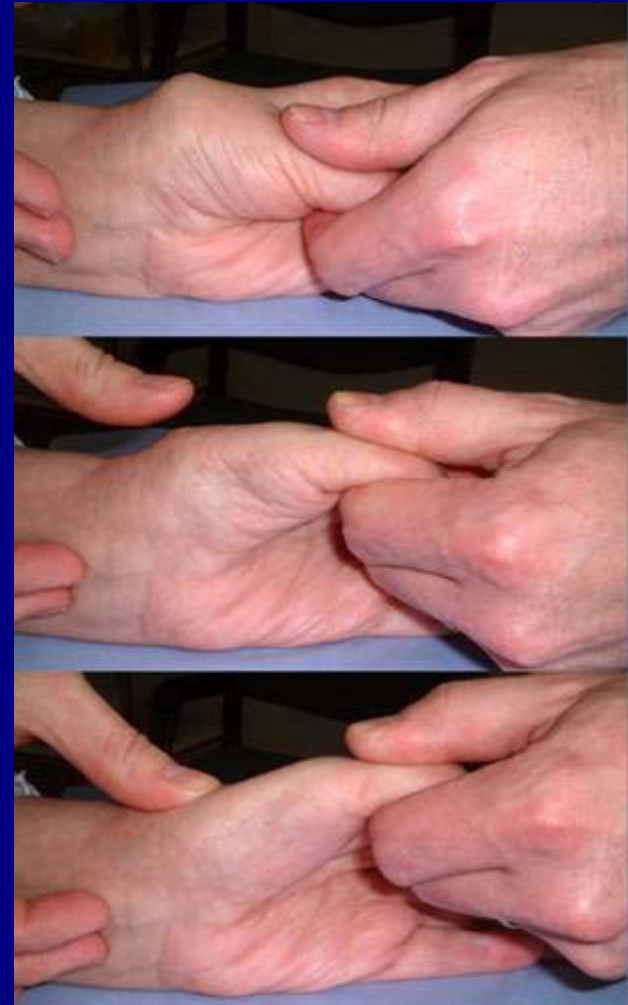
# Quantify

- Carpal tunnel syndrome
- Cubital tunnel syndrome
- Flexor tenosynovitis
- De Quervain's tenovaginitis
- Sagittal band rupture
- Dupuytren's contracture**
- TMCJ osteoarthritis
- STT osteoarthritis
- PTq osteoarthritis
- DRUJ osteoarthritis
- TFCC degeneration
- Digital osteoarthritis
- Other




# Provoke

- Carpal tunnel syndrome
- Cubital tunnel syndrome
- Flexor tenosynovitis
- De Quervain's tenovaginitis
- Sagittal band rupture
- Dupuytren's contracture
- TMCJ osteoarthritis**
- STT osteoarthritis
- PTq osteoarthritis
- DRUJ osteoarthritis
- TFCC degeneration
- Digital osteoarthritis
- Other



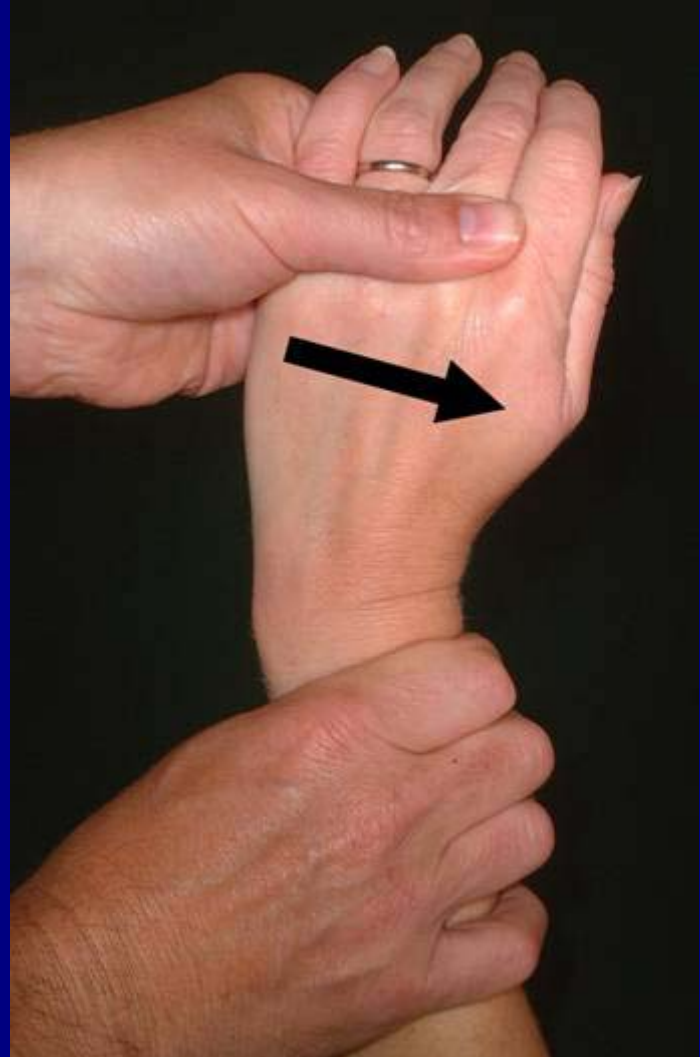
# Quantify

Carpal tunnel syndrome  
Cubital tunnel syndrome  
Flexor tenosynovitis  
De Quervain's tenovaginitis  
Sagittal band rupture  
Dupuytren's contracture  
**TMCJ osteoarthritis**  
STT osteoarthritis  
PTq osteoarthritis  
DRUJ osteoarthritis  
TFCC degeneration  
Digital osteoarthritis  
Other



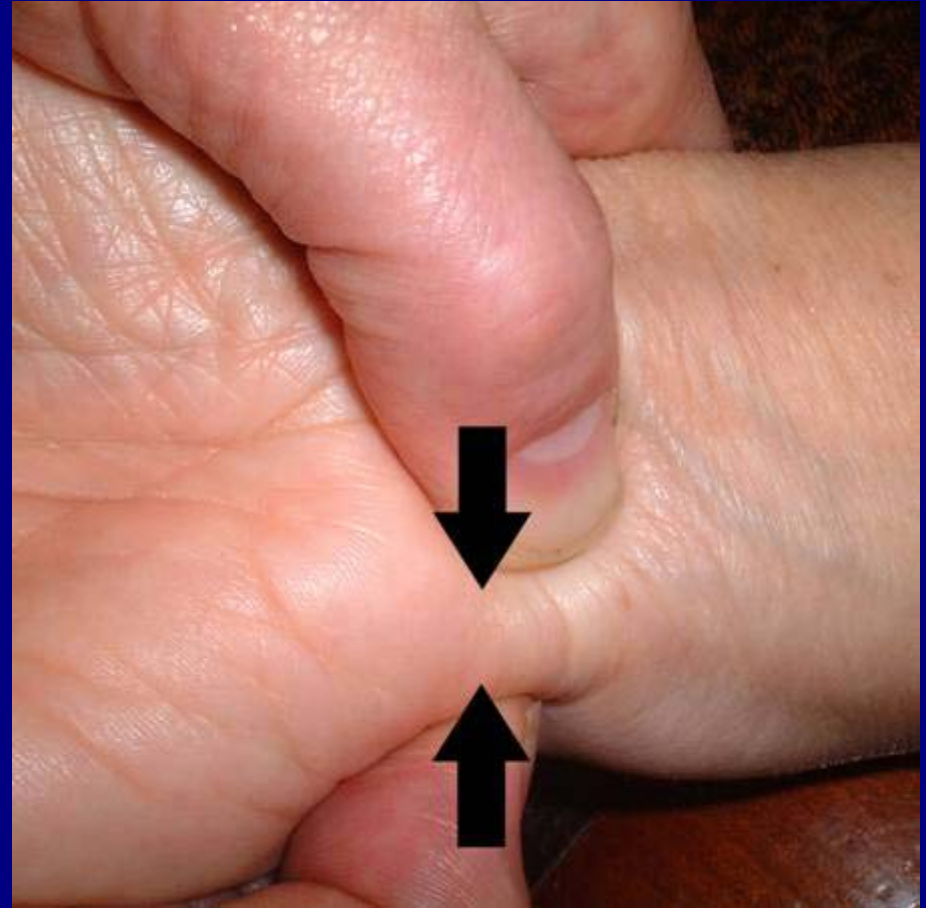
# Provoke

- Carpal tunnel syndrome
- Cubital tunnel syndrome
- Flexor tenosynovitis
- De Quervain's tenovaginitis
- Sagittal band rupture
- Dupuytren's contracture
- TMCJ osteoarthritis
- STT osteoarthritis**
- PTq osteoarthritis
- DRUJ osteoarthritis
- TFCC degeneration
- Digital osteoarthritis
- Other



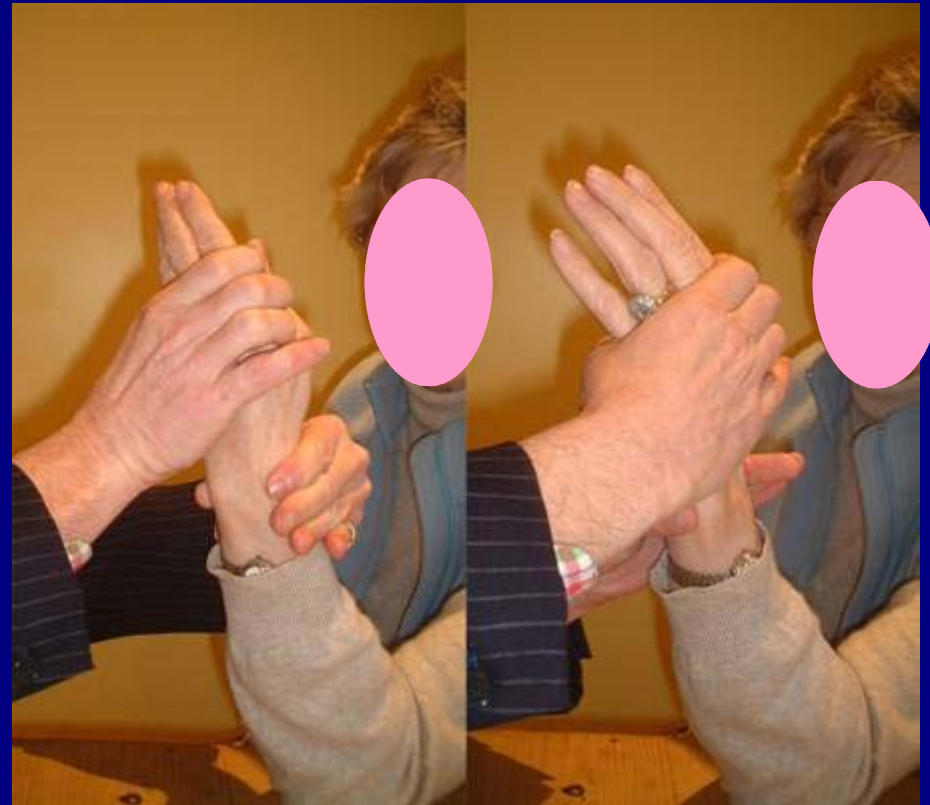# Provoke

- Carpal tunnel syndrome
- Cubital tunnel syndrome
- Flexor tenosynovitis
- De Quervain's tenovaginitis
- Sagittal band rupture
- Dupuytren's contracture
- TMCJ osteoarthritis
- STT osteoarthritis
- PTq osteoarthritis**
- DRUJ osteoarthritis
- TFCC degeneration
- Digital osteoarthritis
- Other



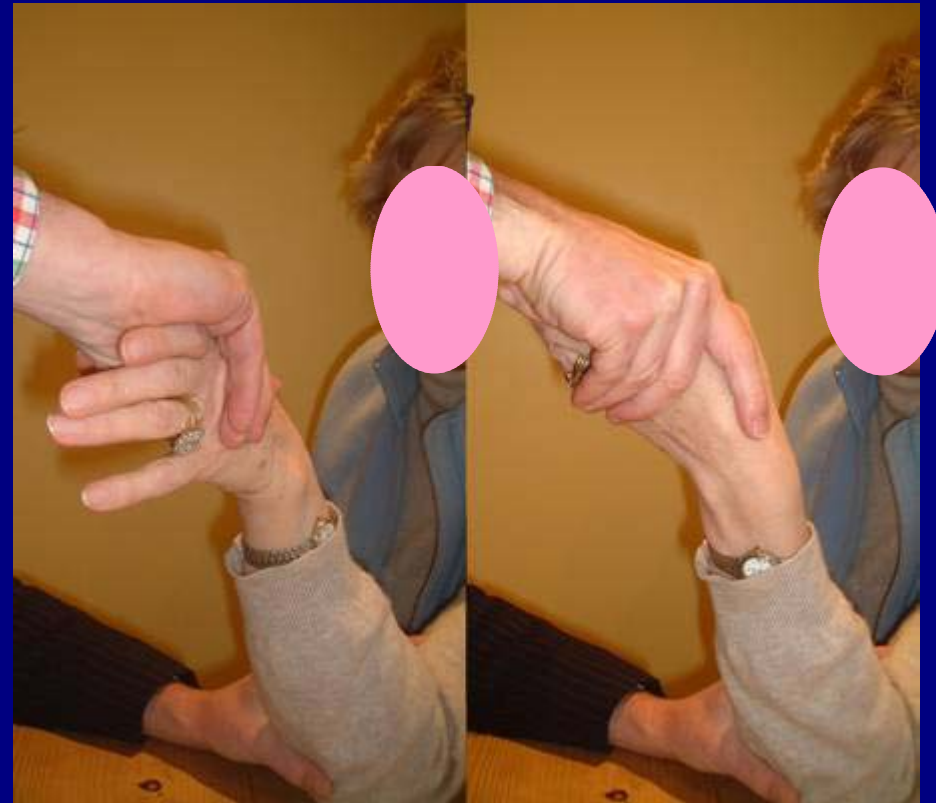# Provoke

- Carpal tunnel syndrome
- Cubital tunnel syndrome
- Flexor tenosynovitis
- De Quervain's tenovaginitis
- Sagittal band rupture
- Dupuytren's contracture
- TMCJ osteoarthritis
- STT osteoarthritis
- PTq osteoarthritis
- DRUJ osteoarthritis**
- TFCC degeneration
- Digital osteoarthritis
- Other



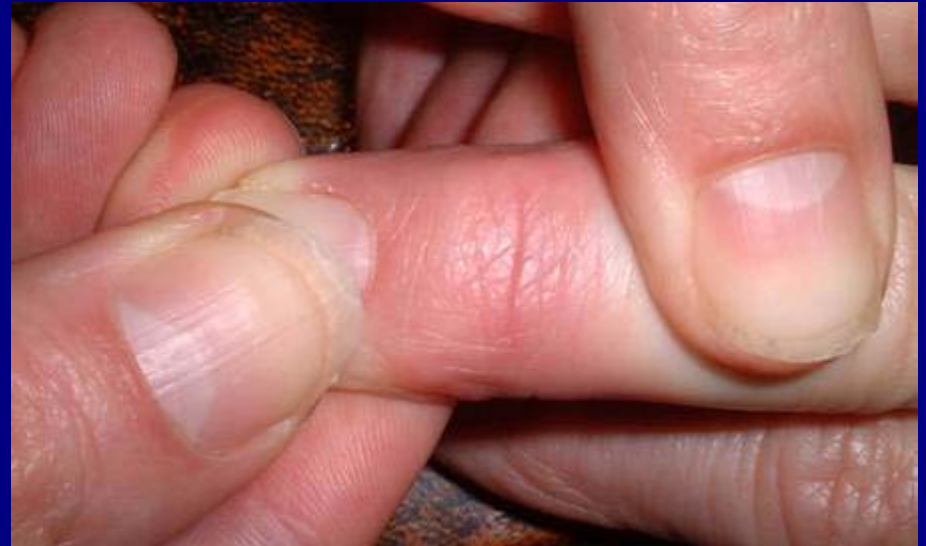# Provoke

- Carpal tunnel syndrome
- Cubital tunnel syndrome
- Flexor tenosynovitis
- De Quervain's tenovaginitis
- Sagittal band rupture
- Dupuytren's contracture
- TMCJ osteoarthritis
- STT osteoarthritis
- PTq osteoarthritis
- DRUJ osteoarthritis
- TFCC degeneration**
- Digital osteoarthritis
- Other



# Provoke

- Carpal tunnel syndrome
- Cubital tunnel syndrome
- Flexor tenosynovitis
- De Quervain's tenovaginitis
- Sagittal band rupture
- Dupuytren's contracture
- TMCJ osteoarthritis
- STT osteoarthritis
- PTq osteoarthritis
- DRUJ osteoarthritis
- TFCC degeneration
- Digital osteoarthritis**
- Other



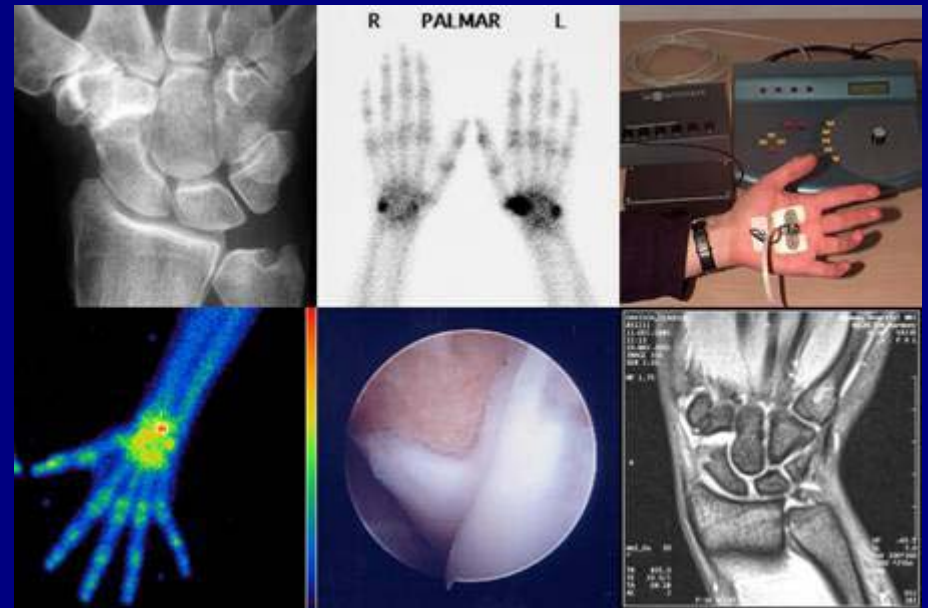
# Sequence

Diagnosis

Quantification

Investigations

Treatment



# Sequence

Diagnosis

Quantification

Investigations

Treatment

Procedure details					
Procedure: <b>Right little dermofasciectomy ± Joint release</b>					
Comments(holidays,transport, medical problems) <b>Splinting to be arranged at Medway</b>					
Priority		Admission		UNSUITABLE OP <input type="checkbox"/>	
URGENT	<input type="checkbox"/>	DAY CASE	<input checked="" type="checkbox"/>	SOCIAL STATUS	<input type="checkbox"/>
SOON	<input type="checkbox"/>	INPATIENT *	<input type="checkbox"/>	TRAVELLING DISTANCE	<input type="checkbox"/>
ROUTINE	<input checked="" type="checkbox"/>	* Reason NOT day case →		MEDICALLY UNFIT	<input type="checkbox"/>
				BMI> 35	<input type="checkbox"/>
Operation by		Anaesthetic		Estimate Theatre Time	
CONSULTANT	<input type="checkbox"/>	GENERAL	<input type="checkbox"/>	0-30 mins	<input type="checkbox"/>
REG	<input checked="" type="checkbox"/>	LOCAL	<input type="checkbox"/>	2-3 hours	<input type="checkbox"/>
ANY	<input type="checkbox"/>	REGIONAL	<input checked="" type="checkbox"/>	30 mins – 1 hour	<input type="checkbox"/>
				1 – 2 hours	<input checked="" type="checkbox"/>
				*Estimated at .....	

