

# ENDOSCOPIC CARPAL TUNNEL RELEASE

Attitudes	"Risk of complications outweighs potential advantages" "Slow" "Risky" "Expensive" "No advantages"	
CTR	Scar tenderness in 19% of hands when assessed at least 10 months after surgery (Kluge et al. 1996, 21B, 205).	
	<b>No true internervous plane</b> (Martin et al. JHS 1996, 21A 634).	
Indications	<b>Pros</b> Scarring minimised Palmar muscles preserved Comfort Power recovery	<b>Cons</b> Difficult Slow Cost Complications
Techniques	1 Portal 2 Portal	Agee Chow
Technique	Anaesthesia Incision Preparation of tunnel Division of retinaculum	
Tourniquet time	Mean = 7.0 minutes (Range = 5-12)	
Technical problems	<b>Convert to OCTR. Better safe than sorry</b>	
Conversion	Total conversions Unsatisfactory vision Tunnel too tight Inadequate vision Tourniquet failure Aberrant anatomy	25 7 9 6 1 2 (4.4% of 565) ScJPRS 2003, 373, 60-4
Access	Study of 100 ECTR. (Schonauer JHS 1999, 24B, 6-8) Tightness assessed by surgeon and graded Loose Intermediate Tight Conversion to OCTR	
	1 2 3 4	
	<b>Access appears to more difficult in small patients</b>	
Specific complications	Ulnar artery division <sup>1</sup> Median nerve division <sup>2</sup> Flexor tendon division <sup>3</sup> Digital nerve division <sup>4</sup> Digital nerve neuropraxia <sup>5</sup> Ulnar neuropraxia Ulnar nerve division Superficial palmar arch division <sup>8</sup> Incomplete release <sup>8</sup>	<sup>1</sup> Thomas, The Hand 1993, Vol 4. <sup>2</sup> Feinstein, JHS 1993, 18A, 451. <sup>3</sup> Scoggin, Arthroscopy 1992, 8:3, 363 <sup>4</sup> Kelly et al., JHS 1994, 19B, 18. <sup>5</sup> Atroshi, JHS 1997, 22B, 42-7 <sup>6</sup> Nath, JHS 1993, 18A, 896. <sup>7</sup> Agee, JHS 1992, 17A, 987. <sup>8</sup> Shinya, JHS 1995, 20B, 222 <sup>9</sup> Erdmann, JHS 1994, 19B, 5
Complications	11 complications in 107 hands (10%) (Shinya, JHS 1995, 20B, 222) Incomplete release Superficial arch laceration RSD Palmar fasciitis Wound inflammation	
	4 1 2 1 3	

## ENDOSCOPIC CARPAL TUNNEL RELEASE

### Complications

565 Wrists, Agee (HJCRB)		
Pillar pain	8	1.5%
Digital neurapraxia	6	1.0%
Median nerve contusion	3	0.5%
Incomplete release	3	0.5%
Wound infection	3	0.5%
Tender scar	1	0.2%
RSD	1	0.2%
<b>Total</b>	<b>25</b>	<b>4.4%</b>

### Complications

1402 patients, 8 Studies, Chow & Agee (Shinya JHS 1995, 20B, 222)		
Ulnar neuropraxia	14	1.0%
Recurrence	11	0.8%
Algodystrophy	5	0.4%
Median nerve laceration	4	0.3%
Incomplete release	4	0.3%
Haematoma	4	0.3%
Palmar arch damage	2	0.2%
Median neuropraxia	1	0.1%
Infection	3	0.2%
Palmar fasciitis	1	0.1%
Other	2	0.2%
<b>Total</b>	<b>50</b>	<b>(3.6%)</b>

### Complications

Prospective, multicentre, Agee (Agee JHS 1995, 20A, 165)		
1049 ECTR in 988 patients		
Conversion to OCTR	26	
Sensory loss*	2	*Digital nerve, palmar branch
Neuropraxia	7	

### Complications

Questionnaire to ASSH (Palmer et al., JHS 1999, 24A, 561)  
 37% of surgeons had experienced a major complication with ECTR  
 9% of surgeons had experienced a major complication with OCTR

Group	ECTR	OCTR
Responses	708	616
Median nerve	100	147
Ulnar nerve	88	29
Digital nerve	77	54
Vessel	121	34
Tendon	69	19

### Complications

Literature review (Boeckstyns & Sorensen, JHS 1999, 24B, 9)		
Group	ECTR	OCTR
Patients in controlled studies	1029	1203
Permanent nerve problem	4	2
Transient nerve problem	46	12
Tendon injury	1	1
Other	12	9

**Transient nerve problems seem to be commoner after ECTR**

## ECTR vs. OCTR

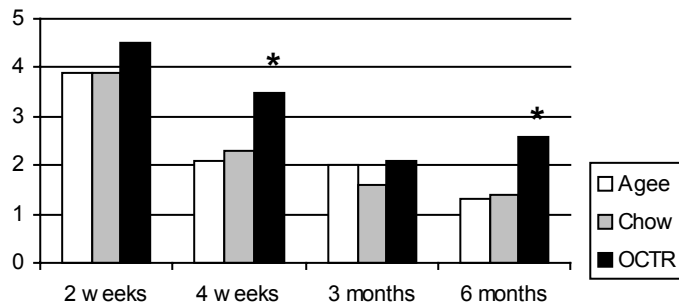
### Clinical studies

Prospective, Non-randomised (Palmer et al. Arthroscopy 1993, 9, 498)

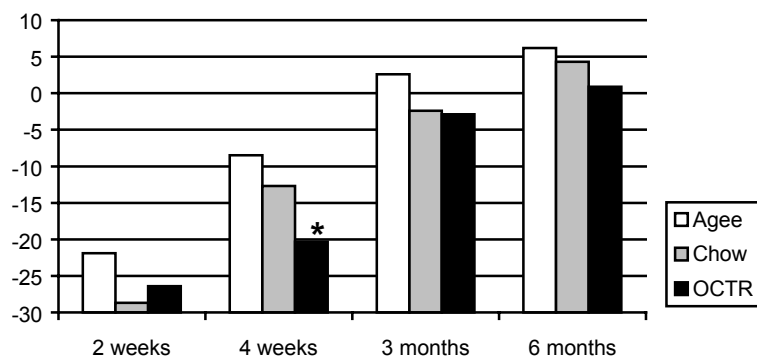
Groups	Agee	Chow	OCTR
Patients (n)	90	72	49
Paraesthesiae (n)	9	9	5
Recurrence (n)	2	3	0
Return to work (days)	20.7	27.9	44.1*

# ENDOSCOPIC CARPAL TUNNEL RELEASE

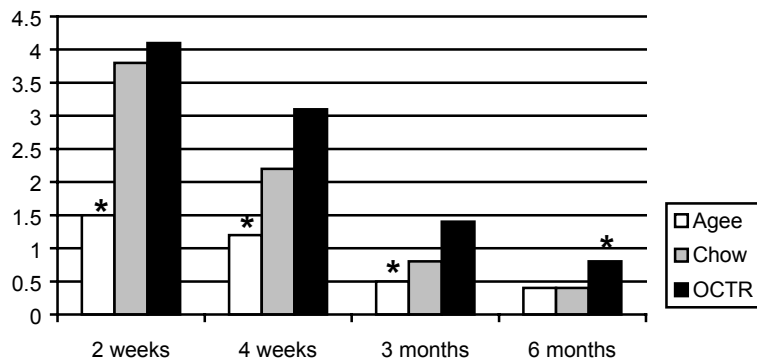
Pain Score



Power (lb) (post-op vs. pre-op)



Scar tenderness score



## Clinical studies

Prospective randomised, Chow . (Jacobsen & Rahme JHS 1996, 21B, 202)

Group	OCTR	ECTR
Wrists (n)	16	16
Sick-leave	19 (0-42)	17 (0-31)

3 transient neuropraxia in ECTR group

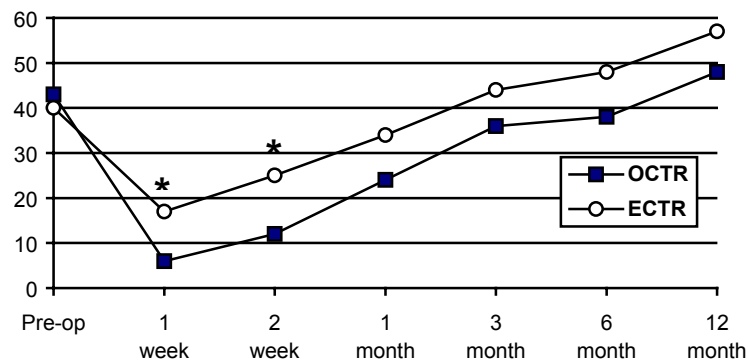
# ENDOSCOPIC CARPAL TUNNEL RELEASE

Clinical studies

Prospective, randomised, Chow. (Erdman, JHS 1994, 19B, 5)

Group	OCTR	ECTR
Patients	52	53
Neuropraxia	0	1
Infection	1	0
Failure	0	1
Scar problem	6	0
Return to work (d)	39	14

Grip strength (lb)



Clinical studies

Prospective, non-randomised, single port (Worseg et al. BJPS 1996, 49, 1)

Group	OCTR	ECTR
Wrists (n)	62	64
Surgery time (min)	21	25
Scar tenderness		Better
Nerve recovery	Equal	Equal
ADL		Better
Grip strength		Better

3ECTR converted to OCTR, 1 ECTR palmar arch division

Clinical studies

Prospective, randomised, Agee (Agee JHS 1992, 17A, 987)

Group	OCTR	ECTR
Wrists (n)	65	82
Nerve recovery	Equal	Equal
Scar tenderness		Better

## ENDOSCOPIC CARPAL TUNNEL RELEASE

Return to work (d)	46.5	25.0
Return to ADL (d)	13	5
Grip strength		Better
Recurrence	0	2
Ulnar neuropraxia	0	2

Clinical studies

Retrospective, unrandomised, Agee, questionnaire (Bande JHS 1994, 19B, 14.)

Group	OCTR	ECTR
Wrists (n)	58	44
Patient satisfaction	96%	97%
“Altered sensation”	22%	23%
“Lost grip strength”	35%	34%
“Scar tenderness”	6%	10%

3 conversions to OCTR  
No significant complications

Clinical studies

Prospective, randomised, Chow (Dumontier JHS, 1995, 20B, 658)

Group	OCTR	ECTR
Wrists (n)	40	56
Pain	Equal	Equal
Sensory recovery	Equal	Equal
Sick leave	Equal	Equal
Grip strength		Better

2 RSD in each group

Conclusions

Improved recovery may outweigh potential complications  
Fast, safe and efficient  
Transient nerve problems seem to be commoner after ECTR  
Particularly suitable for bilateral disease and patients with manually demanding jobs  
Access may be difficult in small patients  
Convert quickly to OCTR if problems are encountered