

# OSTEOARTHRITIS - FINGERS

DIPJ & thumb IPJ

Arthrodesis  
Arthroplasty

PIPJ

**Arthrodesis**  
Predictable  
Definitive  
No contraindications  
Stiff

**Arthroplasty**  
Unpredictable  
Limited life  
Contra-indications (Bone stock, stability)  
Mobile (but not very)

MCPJ

Arthroplasty  
Arthrodesis

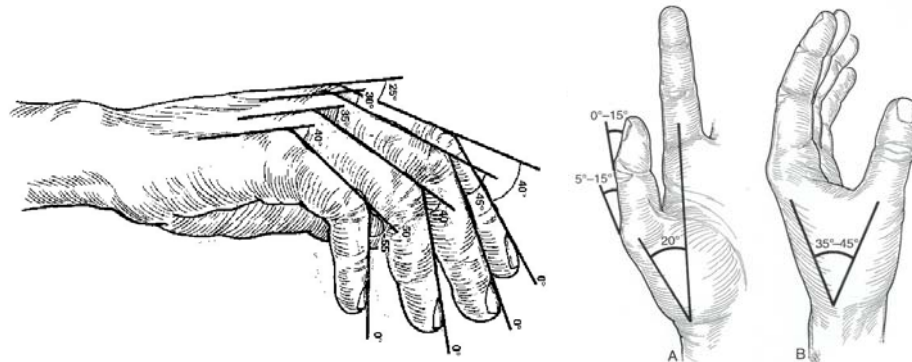
## Arthrodesis

Objective

“A good digital arthrodesis provides a painless and stable union in a proper position and in a reasonable space of time” (Moberg 1960)

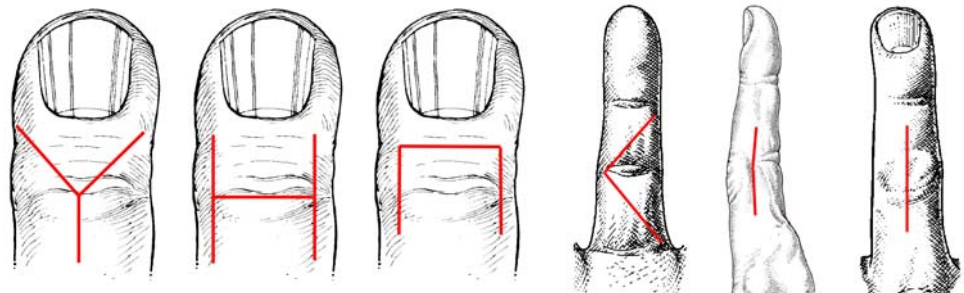
Position

Function versus Cosmesis  
Restore pinch & tripod



Technical errors

Frayed flaps  
Tattered tendons  
'Orrible orientation  
Wrong resection  
Burning bone  
Culpable compression  
Awful aftercare



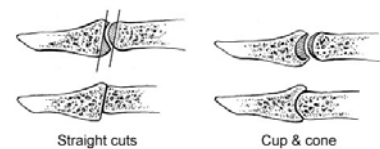
Incisions

Blood supply  
Access  
Adjustable

Bone preparation

**Straight cut**  
Saw  
Rapid  
Inflexible  
Some stability

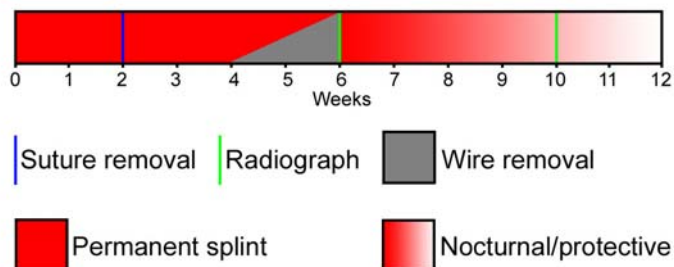
**Cup & Cone**  
Reamers  
Fiddly  
Adjustable  
Unstable



# OSTEOARTHRITIS - FINGERS

- K – wires
  - + Simple
  - + Available & cheap
  - ✗ Stability
  - ✗ Control (angle/rotation)
  - ✗ Distraction
  - ✗ Pin- track infection
  - ✗ Tendon irritation
  
- Wire Loops (90°- 90°)
  - + Available & cheap
  - + Compression
  - + Stability
  - ✗ Technically difficult
  - ✗ Malposition
  - ✗ Tendon irritation
  - ✗ Fixation failure
  
- K-wire and IO loop
  - + Simple
  - + Available & cheap
  - + Compression
  - + Stability
  - ✗ Irritation
  - ✗ Wire removal
  
- Tension band wiring
  - + Available & cheap
  - + Strong
  - + Compression
  - + Good rate of union
  - ✗ Technically demanding
  - ✗ Wire removal
  
- Lag screw
  - + Simple
  - + Compression
  - ✗ Stability
  - ✗ Control (angle/rotation)
  
- Plate fixation
  - + Stability
  - + Control (angle/rotation)
  - ✗ Wide exposure
  - ✗ Distraction
  - ✗ Tendon adhesions
  - ✗ Plate removal
  
- Rehabilitation
 

Often a complete shambles  
 No splint, wrong splint, wrong time  
 No X-Rays, wrong time, misinterpreted  
 No advice, wrong advice

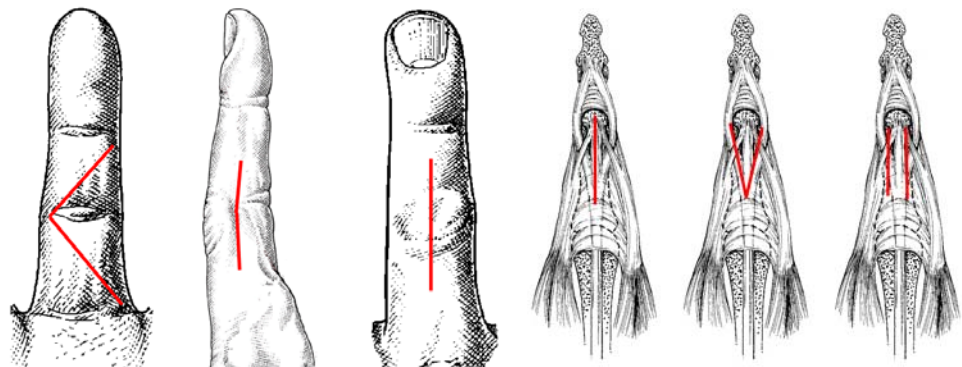


# OSTEOARTHRITIS - FINGERS

Complications	Infection Vascular compromise Wire prominence & migration Nail distortion (DIPJ) Malunion Non-union																																		
Non-union rate	<table border="0"> <tr> <td colspan="2">Tension band wire</td> </tr> <tr> <td>Pardini et al Hand 1982, 14, 291-4</td> <td>0%</td> </tr> <tr> <td>Allende et al JHS 1980, 5A, 269-271</td> <td>0%</td> </tr> <tr> <td colspan="2">Interosseous wires</td> </tr> <tr> <td>Zimmerman Orthopaedics 1989, 12, 99-104</td> <td>0%</td> </tr> <tr> <td>Lister JHS 1978, 3, 427-435</td> <td>9 - 12%</td> </tr> <tr> <td colspan="2">AO screws</td> </tr> <tr> <td>Buck-Gramcko in The Hand(Tubiana) p703</td> <td>8%</td> </tr> <tr> <td colspan="2">Herbert screw</td> </tr> <tr> <td>Herbert JHS 1984, 9B, 167-8</td> <td>0%</td> </tr> <tr> <td>Ayres JHS 1988, 13A, 600-603</td> <td>2%</td> </tr> <tr> <td colspan="2">Cup &amp; cone +screw</td> </tr> <tr> <td>Goldie JHS 2003, 28B, 590-2</td> <td>0%</td> </tr> <tr> <td colspan="2">'Pepperpot' + IO wires</td> </tr> <tr> <td>Shanker JHS 2002, 27B, 430-2</td> <td>0 - 10%</td> </tr> <tr> <td colspan="2">Harrison – Nicholle</td> </tr> <tr> <td>Sabbagh JHS, 2001, 26B, 568-571</td> <td>15%</td> </tr> </table>	Tension band wire		Pardini et al Hand 1982, 14, 291-4	0%	Allende et al JHS 1980, 5A, 269-271	0%	Interosseous wires		Zimmerman Orthopaedics 1989, 12, 99-104	0%	Lister JHS 1978, 3, 427-435	9 - 12%	AO screws		Buck-Gramcko in The Hand(Tubiana) p703	8%	Herbert screw		Herbert JHS 1984, 9B, 167-8	0%	Ayres JHS 1988, 13A, 600-603	2%	Cup & cone +screw		Goldie JHS 2003, 28B, 590-2	0%	'Pepperpot' + IO wires		Shanker JHS 2002, 27B, 430-2	0 - 10%	Harrison – Nicholle		Sabbagh JHS, 2001, 26B, 568-571	15%
Tension band wire																																			
Pardini et al Hand 1982, 14, 291-4	0%																																		
Allende et al JHS 1980, 5A, 269-271	0%																																		
Interosseous wires																																			
Zimmerman Orthopaedics 1989, 12, 99-104	0%																																		
Lister JHS 1978, 3, 427-435	9 - 12%																																		
AO screws																																			
Buck-Gramcko in The Hand(Tubiana) p703	8%																																		
Herbert screw																																			
Herbert JHS 1984, 9B, 167-8	0%																																		
Ayres JHS 1988, 13A, 600-603	2%																																		
Cup & cone +screw																																			
Goldie JHS 2003, 28B, 590-2	0%																																		
'Pepperpot' + IO wires																																			
Shanker JHS 2002, 27B, 430-2	0 - 10%																																		
Harrison – Nicholle																																			
Sabbagh JHS, 2001, 26B, 568-571	15%																																		
Failed arthrodesis	Plate fixation with cancellous bone graft Moberg dowel graft																																		

## Arthroplasty

Contra-indications	History of infection Poor bone-stock Joint instability Tendon imbalance Established stiffness High physical demand Uncompliant patient
--------------------	--



# OSTEOARTHRITIS - FINGERS

Surgical approaches

- Volar
- Lateral
- Dorsal
- Chamay
- Central split
- Tendon-sparing

Volar Approach

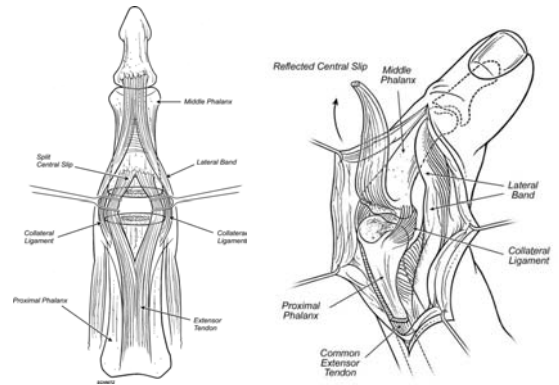
- + Preserves extensors
- + Enables early mobilization
- + Flexor synovectomy
- + Release of contracture
- ✗ Technically demanding
- ✗ Orientation difficult
- ✗ Volar swelling

Lateral Approach

- + Early mobilization
- + Less stiffness?
- ✗ Orientation difficult
- ✗ Soft tissue balance
- ✗ Lateral instability

Dorsal – Chamay

- + Good view
- + Easy orientation
- + Preserves central slip
- + Adjustment of extensor
- ✗ Risk of adhesions
- ✗ Intensive therapy
- ✗ Motivated patient



Dorsal - midline split

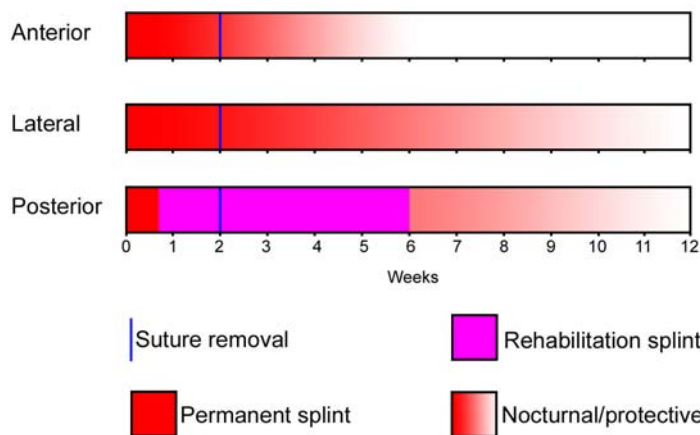
- + Clear view
- + Easy orientation
- + Better access to P2
- ✗ Risk to central slip

Types

- Soft tissue
- Prosthetic
  - Silastic
  - Pyrocarbon surface
  - Other surface
  - Osseointegrated

Rehabilitation

Varies according to surgical approach  
Directed to soft tissue repairs rather than prosthesis



# OSTEOARTHRITIS - FINGERS

## PIPJ Swanson's

### Advantages

Technically easy  
Some inherent stability

### Results

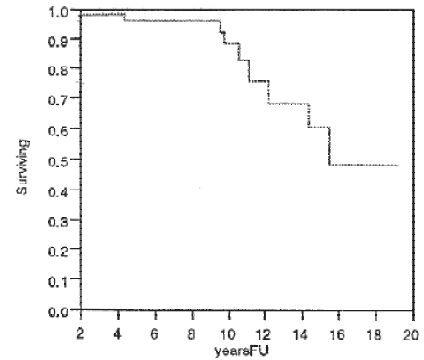
Pain relief in 90-95%  
Average ROM 50-60°  
Instability (esp. Index)  
Good results in 60-90% (5yr FU)  
Poorer outcomes in stiff fingers  
Results unaffected by approach

### Complications

Stiffness  
Infection  
Implant fracture  
Bone fracture  
Excessive wear  
Silastic synovitis  
Instability

### Overview

Simple, reliable procedure in low demand patients  
Limited movement  
Limited life span in younger patients  
Failure with bone loss after 5 – 10 yrs  
Difficult salvage



## PIPJ Pyrocarbon implants

### Pyrocarbon

Elastic modulus similar to cortical bone  
High strength  
Fatigue & wear resistance  
Chemically stable  
Artificial heart valve 1969  
Digital implants 1979

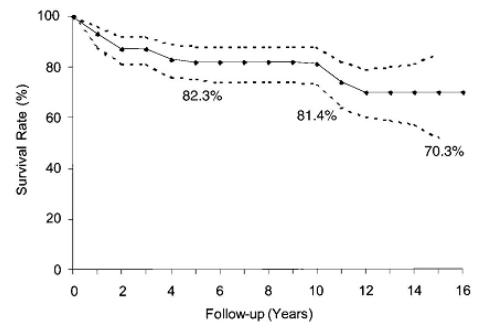


### Disadvantages

Technically demanding  
Little inherent stability  
Squeaky!

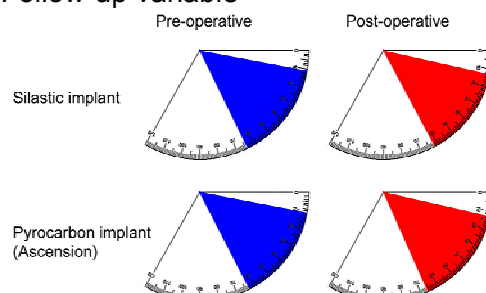
### Complications

Stiffness  
Infection  
Loosening  
Dislocation  
Bone fracture  
Instability



### Outcomes

Swanson vs Pyrocarbon (Branam et al. JHS 2007, 32A, 775-788)  
PIPJ arthroplasty in osteoarthritis  
Retrospective, non-randomized  
Follow-up variable



## OSTEOARTHRITIS - FINGERS

<b>Demographics</b>	Silastic	Pyrocarbon
Patients	13	9
Joints	22	19
Follow-up(m)	45	19

<b>Revisions</b>	Silastic	Pyrocarbon
Joints	22	19
Deformity	2	
Sepsis	1	

<b>Complications</b>	Silastic	Pyrocarbon
Implant fracture	1	
Cellulitis	1	
Nerve injury	1	
Per-op fracture		2
Dislocations		2
Loosening		2
Squeaking		8

### Conclusions

- All** Principal indication is pain
- DIPJ** Fuse all  
Beware delayed and non-unions
- PIPJ** Fuse most  
Be realistic about likely movement
- MCPJ** Arthroplasty superior to arthrodesis  
Pyrocarbon best